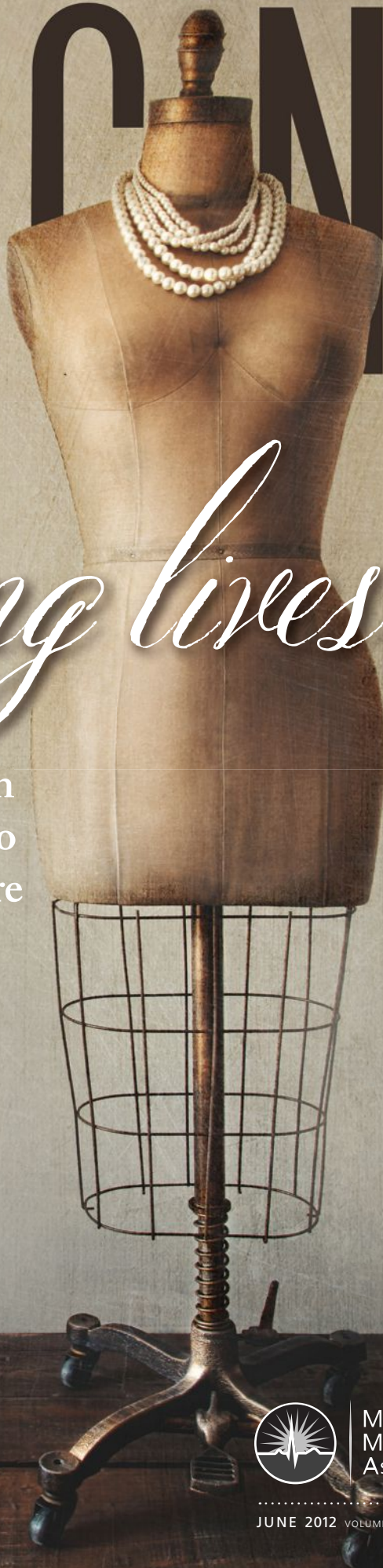

minnesota

MEDICINE



Reshaping lives

Breast reconstruction
is now integral to
cancer care

ALSO INSIDE:

Top **plastic surgery** procedures

Residents on a **mission**

Trends in **hand surgery**



MINNESOTA
MEDICAL
ASSOCIATION

JUNE 2012

CONTENTS



p.20

COVER STORY

Reshaping lives

| By J. Trout Lowen

Breast reconstruction is now integral to cancer care.

PULSE

- 8 In brief**
Who put the “plastic” in plastic surgery, the lit on leeches, botaxes.
- 9 Looking good** | By Carmen Peota
Top plastic surgery procedures for men and women.
- 10 On a mission** | By Suzy Frisch
For University of Minnesota plastic surgery residents, giving is part of learning.
- 12 Comfortable in their skin** | By Adrienne Foley
Bariatric surgery patients are turning to plastic surgeons to help them deal with the aftermath of extreme weight loss.
- 16 The making of a plastic surgeon** | By Kim Kiser
There are now two routes to becoming a plastic surgeon.

CLINICAL & HEALTH AFFAIRS

36 Current Trends in Hand Surgery

| By Loree K. Kalliainen, M.D., M.A., FACS

41 The Evolution of Wrinkle Removal: Use of Lasers and Other Devices in Facial Rejuvenation

| By Richard H. Tholen, M.D., FACS

46 Craniosynostosis and Deformational Plagiocephaly: When and How to Intervene

| By Robert J. Wood, M.D., FACS, FAAP

THE PHYSICIAN ADVOCATE

The MMA's monthly report on policy, people and politics

27

LEGISLATIVE REVIEW
Revising and improving previous work is theme for 2012

- 31 THE EXAMINING ROOM
MMA members weigh in on the 2012 legislative session
- 32 LEGAL UPDATE
MMA continues legal efforts in two state cases
- 32 MEET A MEMBER
Dionne Hart, M.D.
- 34 VIEWPOINT
Lessons for the future
- 35 MMA NEWS IN REVIEW



END NOTES

56 Be careful what you fish for | By Craig Bowron, M.D.
Encourage safe consumption of finny fare.

ALSO INSIDE

- 4 Editor's note
- 6 Letters
- 51 Index of advertisers
- 51 Employment opportunities

Minnesota Medicine is intended to serve as a credible forum for presenting information and ideas affecting Minnesota physicians and their practices. The content of articles and the opinions expressed in *Minnesota Medicine* do not represent the official policy of the Minnesota Medical Association unless this is specified. The publication of an advertisement does not imply MMA endorsement or sponsorship.

To Submit an Article
Contact Carmen Peota at cpeota@mnmed.org.

The editors reserve the right to reject editorial, scientific, or advertising material submitted for publication in *Minnesota Medicine*. The views expressed in this journal do not necessarily represent those of the Minnesota Medical Association, its editors, or any of its constituents.

MINNESOTA MEDICINE

Contact Us

Minnesota Medicine, 1300 Godward Street, Ste 2500, Minneapolis, MN 55413. Phone: 612/378-1875 or 800/DIAL MMA
Email: mm@mnmed.org
Web: minnesotamedicine.com

Owner and Publisher

Minnesota Medical Association

Editor in Chief

Charles R. Meyer, M.D.

Editors

Carmen Peota
Kim Kiser

MMA Communications Director

Terry Ruane

Physician Advocate Writer

Dan Hauser

Art Director

Kathryn Forss

Advisory Committee

Zubin Agarwal
Maria Carrow, M.D.
Aaron Crosby
Donald L. Deye, M.D.
Mark Eggen, M.D.
Barbara Elliott, Ph.D.
Jon S. Hallberg, M.D.
Neal Holtan, M.D.
Peter J. Kernahan, M.D.
Patricia J. Lindholm, M.D.
Robert K. Meiches, M.D.
Gregory Plotnikoff, M.D.
Martin Stillman, M.D., J.D.
Barbara P. Yawn, M.D.
Anjali Wilcox
Therese Zink, M.D., M.P.H.

Copyright & Post Office Entry

Minnesota Medicine (ISSN 0026-556X [print] and 1945-3051 [online]) is published each month by the Minnesota Medical Association, 1300 Godward Street NE, Suite 2500, Minneapolis, MN 55413. Copyright 2012. Permission to reproduce editorial material in this magazine must be obtained from *Minnesota Medicine*. Periodicals postage paid at Minneapolis, Minnesota, and at additional mailing offices. POSTMASTER, send address changes to *Minnesota Medicine*, 1300 Godward Street, Ste 2500, Minneapolis, MN 55413.

Subscriptions

Annual subscription - \$45 (U.S.), \$80 (all international)

Missing Issues and Back Issues

Missing issues will be replaced for paid subscribers at no additional charge if notification is received within six months of the publication date. Replacement of any issues more than six months old will be charged the appropriate single back issue price. Single back issues of *Minnesota Medicine* can be purchased for \$25 (U.S.) and \$30 (Canada, Mexico, and other international). Send a copy of your mailing label and orders to Kristin Drews, 1300 Godward Street, Ste 2500, Minneapolis, MN 55413 or fax it to 612/378-3875.

To Advertise Contact Jocelyn Cox at 612/623-2880 or jcox@mnmed.org.



MINNESOTA
MEDICAL
ASSOCIATION

President

Lyle J. Swenson, M.D.

President-Elect

Dan Maddox, M.D.

Chair, Board of Trustees

David C. Thorson, M.D.

Secretary/Treasurer

David E. Westgard, M.D.

Speaker of the House

Mark Liebow, M.D.

Vice Speaker of the House

Robert Moravec, M.D.

Past President

Patricia J. Lindholm, M.D.

Chief Executive Officer

Robert K. Meiches, M.D.



Photo by Scott Walker

In plastic surgery, what's appearance and what's function quickly gets blurred.

Two faces of a specialty

*Ben, I just want to say one word, just one word.
Are you listening?
Yes I am.
Plastics.
Exactly how do you mean?
There's a great future in plastics. Will you think about it?
Yes I will.
Nuff said. That's a deal.*

In one of the iconic dialogues in American film, clueless and recently graduated Ben, played by Dustin Hoffman, gets cornered by Mr. McGuire, one of his parents' friends, at a graduation party and told where fame and fortune lie. Many a medical student contemplating residency has envisioned a great future in a different kind of plastics. Indeed in recent years, plastic surgery has been one of the most sought-after residencies. And graduating medical students frequently submit applications to more than 60 programs to nab one of the coveted spots. Perhaps some of those students envision fame and fortune, performing tummy tucks and chin lifts on movie stars and appearing on *Oprah*; but in 2012, there is so much more for them to consider. And glitz and glamour take a back seat to restoring form and function.

Plastic surgery has always had two faces—cosmetic and reconstructive. Classic thinking has plastic surgeons just out of residency building their practice with reconstructive cases gleaned from emergency room trauma and gradually migrating toward the more lucrative, less urgent cosmetic cases. Although that evolution still happens, more and more, plastic surgeons are exploring ways to remold the body not only to make it look better but also to make it work better. Plastic surgeons working with neurosurgeons now remodel crania of infants born with misshapen heads to relieve pressured brains. Hand surgeons,

some of whom are drawn from the ranks of plastic surgeons, transfer nerves, inject contractures and transplant tendons, reconstructing our most versatile appendage to keep it functional. Destitute children in Peru receive the gift of oral function when residents from the University of Minnesota plastic surgery program repair cleft lips and palates.

The cosmetic and the reconstructive merge when plastic surgeons remove excess skin after massive weight loss following bariatric surgery, paring off pounds of sagging skin after the adipose tissue has gone in a procedure dubbed “body contouring.” Although patients would think this improves their function, most insurance plans consider this surgery cosmetic and therefore won't cover it. Yet coverage for surgery that reproduces the contours of the missing breast after mastectomy was mandated by the Women's Health and Cancer Rights Act of 1998. In plastic surgery, what's appearance and what's function quickly gets blurred.

Indeed, plastic surgery procedures frequently push the envelope of the goals of medicine. Do we cure? Do we comfort? Or do we dare to say we enhance the human experience? When talking about breast reconstruction, plastic surgeon Mark Migliori, M.D., states, “It's about productivity, it's about sexuality, it's about personal relationships and it's about satisfaction.” That's a tall order for any branch of medicine.

Hoffman's character never followed Mr. McGuire's advice. He eschewed the siren song of plastics but found lifelong happiness with Elaine. For today's medical school graduates planning careers in plastic surgery, the specialty may not guarantee lifelong happiness but offers a future of professional fascination.

.....
Charles R. Meyer, M.D., can be reached at meyer073@umn.edu.



The Importance of nurses

The article “Remembering the Neediest” by Zubin Agarwal (May, p. 25) caught my eye. For 10 years, I did short-term mission work in the Lake Atitlan region in Guatemala. Going back every year shows one the impact one can make through time and education.

I am glad to see that medical students are offered the opportunity to go to remote areas. And it was refreshing to feel the author’s compassion for the people of Malawi.

I do want to comment on one line in the story. The author states: “Nurses around the country have become largely apathetic about the struggles of their patients.” I’m not sure why a medical student would judge the nursing profession in that way. Is this what is now being taught at Mayo? Do we think physicians and state-of-the-art medical tests are the only answers to global health concerns? If so, it is a sad state.

Education is the key. Education of women, in particular, can change one village at a time. And nurses often are the ones to provide that. The book *Where There Is No Doctor* is a great reference that provides practical, easily understood information on common diseases, with special attention paid to nutrition, infection and disease prevention. It has been used on many of the medical mission trips I

have been on. We educated anyone who wanted to come to our classes. They then spread the information to others in their and surrounding villages.

Jill Lundgren, R.N.
St. Paul

Innovation Is not new

In reading “10 Bright Ideas” (April, p. 18), which highlights innovative physicians, it occurred to me that physician innovation is not only about technology and new advances in treating disease; it is also about helping patients navigate the myriad issues that can affect their access to proper care. There is really nothing new regarding that endeavor. We have all heard how physicians maintained their patients’ access to care during the Depression. That kind of innovation reflects our basic desire to be physicians. Thank you for keeping physicians apprised of current concerns.

Michael R. Busian, M.D.
Morris

SUBSCRIBE TO minnesota MEDICINE



Minnesota Medicine is a leader in providing timely and informative articles about the current state of medicine in Minnesota and the nation. It consistently delivers interesting and pertinent insights and commentary on issues facing providers and patients in the ever-changing health care environment.

Minnesota Medicine has been honored repeatedly by the Minnesota Magazine & Publishing Association for editorial excellence.

Don't miss this opportunity to subscribe to one of the best state medical journals in the nation.

SUBSCRIBE ONLINE:
www.MNMed.org/Magazine_Subscription.html



© _point - Fotolia.com

■ What's in a name

Why "plastic"?

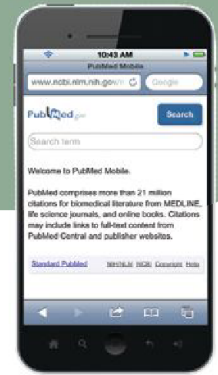
The "plastic" in plastic surgery refers not to substances made from polymers but to the work that is done by the surgeons in this specialty. The term is derived from the Greek *plastikos*, which means to mold or give form. The specialty's name is thought to have been coined in 1839 with the publication of the book *Handbuch der plastischen Chirurgie* by German surgeon Edward Zeiss.

Source: American Society of Plastic and Reconstructive Surgeons.

check this out

PubMed in your pocket

The National Library of Medicine's (NLM) PubMed Mobile app allows you to access the library's 20 million-plus citations from the biomedical literature using your smartphone. Check out this and other NLM apps at www.nlm.nih.gov/mobile/index.html.



■ The lit on leeches

Enough evidence?

Leeches are almost iconic for all that is passé in medicine. However, some physicians and patients are again seeing their potential and are bravely using the slimy creatures to aid in healing following plastic and reconstructive surgeries.

These efforts are the focus of more than a few published articles, most of which recount cases. But the literature on leeches had never really been synthesized. That's what prompted researchers in Wales recently to review reports on leech use. Their search (via PubMed, the Cochrane library and the Centre for Reviews and Dissemination) turned up 227 reported cases in 67 articles published between 1966 and 2009.

Overall, the success rate for leech therapy was 77.89 percent, with a complication rate of about 22 percent. Blood transfusions were required in nearly half of the cases, antibiotics in 80 percent and anti-coagulation therapy in 54 percent.

The authors of the article, which appeared in the March issue of *Microsurgery*, suggested that in the absence of randomized controlled trials, their summary of studies could be used to guide physicians as they make therapeutic decisions and seek consent from patients.

Source: Whitaker IS, Oboumarzouk O, Rosen WM, et al. The efficacy of medicinal leeches in plastic and reconstructive surgery: a systematic review of 277 reported clinical cases. *Microsurgery*. 2012;32(3):240-50.

© Antagrain istockphoto.com

■ Botaxes

Should we tax beauty?

Next month, New Jersey begins phasing out its 6 percent tax on cosmetic procedures, which has brought \$10.8 million into the state each year since it was adopted in 2004. Gov. Chris Christie signed legislation in January to eliminate the tax. The New Jersey Society of Plastic Surgeons led the battle against it, commissioning a study that suggested the state had actually lost revenue because of the tax. Among other things, opponents argued that compliance costs exceeded the amount collected and that patients were leaving the state to have procedures done. The phase-out begins with a rate reduction to 4 percent. The tax is to be abolished by July 1, 2013.

In Minnesota, Rep. Phyllis Kahn has unsuccessfully proposed instituting such a tax in 2007 and then again in 2011. The U.S. Senate attempted to place a 5 percent tax on cosmetic procedures and surgeries to help pay for extending health care coverage as part of the Affordable Care Act. That provision was removed from the final version of the bill.

Meanwhile, Brazil made cosmetic surgery tax-deductible this year.

■ Cosmetic surgery

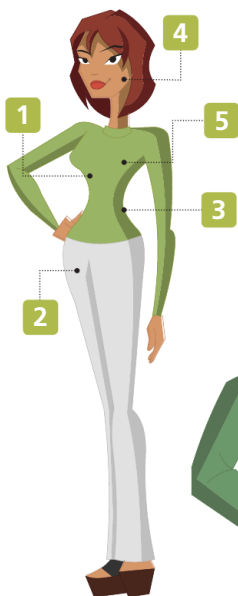Looking good

The FDA allowed the reintroduction of silicone gel breast implants in 2006.

In the past 15 years, there has been a 340% increase in the number of tummy tucks performed in the United States.

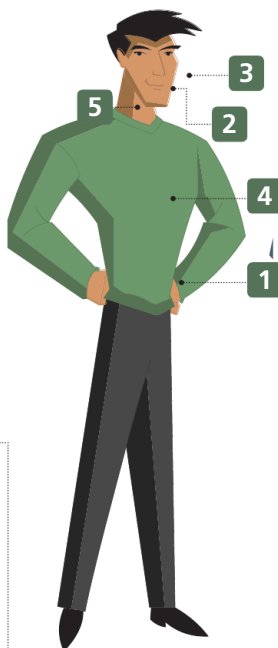
Top 5 procedures for **WOMEN**

- 1 Breast augmentation**
 - Takes 1 to 2 hours
 - 31% used saline implants
 - AVERAGE PHYSICIAN FEE: \$3,694
 - 69% used silicone implants
 - AVERAGE PHYSICIAN FEE: \$3,308
 - Back to work in 1 to 2 weeks
- 2 Lipolasty**
 - Takes 45 minutes to 2 hours
 - AVERAGE PHYSICIAN FEE: \$2,773
 - Back to work in 1 to 2 weeks
- 3 Abdominoplasty**
 - Takes 2 to 5 hours
 - AVERAGE PHYSICIAN FEE: \$5,278
 - Back to work in 2 to 4 weeks
- 4 Blepharoplasty**
 - Takes from 1 to 3 hours
 - AVERAGE PHYSICIAN FEE: \$2,630
 - Back to work within 10 days
- 5 Breast lift**
 - Takes 1½ to 3½ hours
 - AVERAGE PHYSICIAN FEE: \$4,233
 - Back to work in 1 to 2 weeks



Top 5 procedures for **MEN**

- 1 Lipoplasty**
 - Takes 45 minutes to 2 hours
 - AVERAGE PHYSICIAN FEE: \$2,773
 - Back to work in 1 to 2 weeks
- 2 Rhinoplasty**
 - Takes 1 to 2 hours
 - AVERAGE PHYSICIAN FEE: \$4,246
 - Back to work in 7 to 10 days
- 3 Blepharoplasty**
 - Takes from 1 to 3 hours
 - AVERAGE PHYSICIAN FEE: \$2,630
 - Back to work within 10 days
- 4 Gynecomastia**
 - Takes 2 hours
 - AVERAGE PHYSICIAN FEE: \$3,277
 - Back to work in 1 week
- 5 Facelift**
 - Takes 2 to 3 hours
 - AVERAGE PHYSICIAN FEE: \$6,408
 - Back to work within 2 weeks



Americans spent nearly \$10 billion on cosmetic procedures in 2011.



Take it on (and off) the chin

Among both men and women, chin augmentation (jowl adjustment) is the fastest-growing plastic surgery trend, according to the American Society of Plastic Surgeons. The number of chin augmentations increased more than the number of breast augmentation, Botox and liposuction procedures combined in 2011. The largest increase, no surprise, was seen in patients age 40 or older.



Women had 8.6 million (91% of the total) cosmetic procedures done in 2011. That number is up 164% since 1997.



Source: Unless otherwise noted, information is from 2011 Survey Data from the American Society for Aesthetic Plastic Surgery. (Data collected from physicians in plastic surgery, otolaryngology and dermatology.)



Matthew Sherrill, M.D., with a young patient during a mission trip to Peru.

Photos courtesy of Matthew Sherrill

■ A tradition of service

On a mission

For University of Minnesota plastic surgery residents, giving is part of learning. | BY SUZY FRISCH

Matthew Sherrill, M.D., gets emotional thinking about the children with cleft lip and palate he helped during a medical mission to Peru last January. He remembers four kids, ages 1 to 5, in particular whose mothers sent them off in a truck for a two-and-a-half-hour ride down the Andes mountains to the nearest town, where they caught a bus, which took them and their chaperone on another eight-hour journey to a hospital in Lima for surgery.

“Those mothers wanted something more for their children. To give them up, put them on a dump truck and then a bus to allow their kids to better themselves, it affects you,” says Sherrill, a resident in plastic and reconstructive surgery at the University of Minnesota who will be entering private practice in LaCrosse, Wisconsin, this summer.

Sherrill was one of two residents this year who spent a week in Peru as part of the department of plastic and reconstructive surgery’s third-world medical mission elective. During his week-long stay, Sherrill did four or five procedures a day, honing his skills.

But more important, says Frank Pilney, M.D., founder and director of the elective program, the experience instills in residents the desire to do more mission work in developing countries.

“Each year when they graduate, they tell me it was one of the better educational experiences they had; and they get the bug and want to come back,” he says.

It started with a priest

A chance encounter inspired Pilney, an adjunct professor of plastic and reconstructive surgery, to help people in Peru. On his way to Montana from the Twin Cities for a ski trip in 1981, he stopped with his family for Saturday night mass in Fargo. The priest spoke about a recent trip to Peru and showed slides of children with various birth defects he wanted to help. Pilney gave him his card. Later that year, Pilney traveled twice to the city of Trujillo with the priest and worked with two other doctors from Minnesota to treat 470 patients.

By 1983, Pilney and the other volunteers moved their base to the larger Hospital San Juan de Dios in Lima, where they continue to do their mission work. Two years ago, Pilney expanded his medical missions to the city of Arequipa to reach Peru’s more remote areas.

Soon after Pilney started taking mission trips to Peru, other physicians from the university’s plastic and reconstructive surgery department began joining him. There was general senti-

ment that it would be a great experience for residents. With the approval of the head of the department, the elective was established in 1993. Each year, Pilney takes two third-year residents to Peru. Warren Schubert, M.D., chair of plastic and hand surgery at Regions Hospital in St. Paul and a professor at the University of Minnesota, takes one second-year resident to Guatemala, Bolivia, Colombia, Vietnam or the Philippines. Pilney says every third-year resident except one (who was pregnant at the time) has participated in the elective since it began. (Initially, the university covered the residents' costs, but now Pilney pays for them through donations.) The elective is one of a few such programs in the United States.

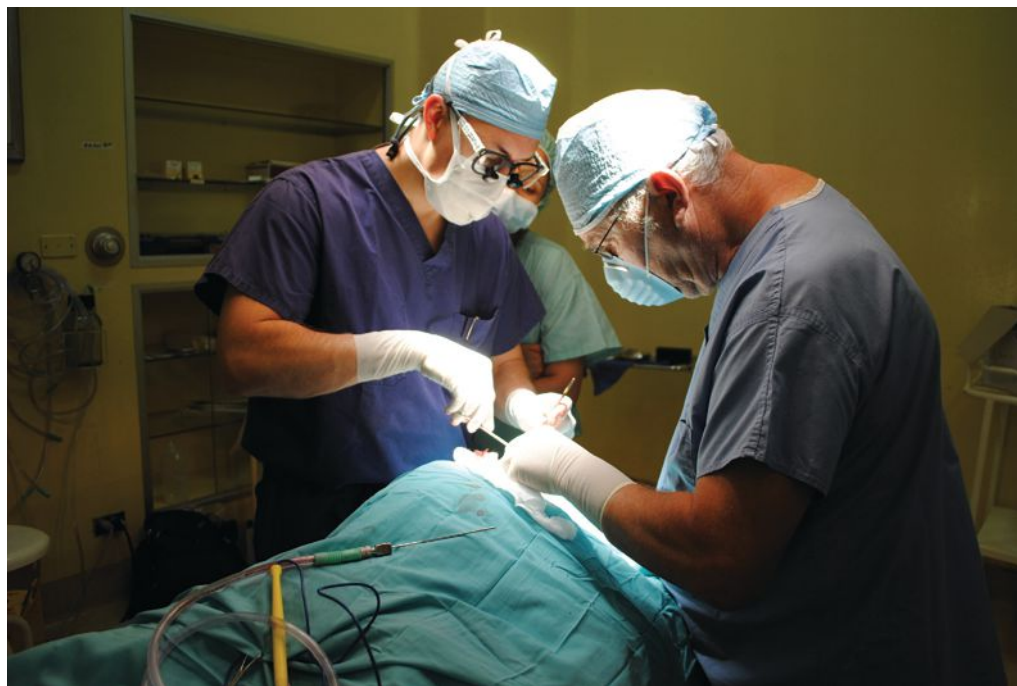The university's elective is an example of the tradition of volunteering among plastic surgeons in Minnesota. An estimated 80 percent have gone on volunteer medical missions, according to Mark Migliori, M.D., a plastic and reconstructive surgeon and clinical adjunct professor in plastic surgery at the university, who also takes two to three mission trips a year.

Changing lives, building skills

Unlike some specialties, plastic surgery lends itself well to short-term missions to third-world countries. Many procedures can be done in more rudimentary operating rooms and don't require high-tech equipment. "Plastic surgery is unique in that you can go into a country and do something quickly to change a person's life," Pilney says.

During his first years in Peru, Pilney says he and his team often operated on people in their 40s and 50s with cleft lips or palates. Now, most of the adult patients have been treated, so volunteers operate on young children and teenagers. Each year, Pilney and the other volunteer surgeons perform about 200 reconstructive surgeries there. "When you look at their medical system, if there wasn't something like our program [those surgeries] wouldn't have been done," Pilney says. "They don't have the ability to cope with it there."

For plastic and reconstructive surgery resident George Dreszer, M.D., mission trips have been an "unbelievable experience." He has been on four, twice to Peru (once with the resident elective) and once each to Colombia and Ecuador with other medical mission programs. He plans to return to Peru as part of Pilney's mission at his own expense, even though he's



Sherrill and Frank Pilney, M.D., founder of the University of Minnesota's third-world medical mission elective, doing a procedure during a mission to Peru.

leaving medical school and residency with a load of student loan debt.


"It's so important," says Dreszer, who will open a practice in Miami later this year. "It's easy to get jaded with the medical system here. Going on these trips, you remember why you became a doctor and why you became a surgeon."

He says the people he cares for are genuinely thankful. "I get as much out of it as the patients do. I learn from them and from the other doctors, and it makes me feel good," he says.

Migliori, who was the second resident to travel with Pilney to Peru, says the experience profoundly influenced his life and career. "Obviously seeing another world and seeing how lucky you are, that has an impact," he explains. "But you also watch the [Peruvian] physicians, and they really have to be renaissance docs—they have to do everything and they are there for their community."

And then there are the patients. Migliori recalls removing a hairy nevus from an 8-year-old boy in Guatemala. The mole covered most of his cheek and part of his neck. He was considered a werewolf and never went to school. Every six months when Migliori returned to Guatemala, he would excise some of the nevus. Five surgeries later, it was completely removed. The boy had a scar but he could finally enter society.

Migliori relishes the moment when mothers see their children for the first time with their defect repaired. "It's exhilarating when they see their child with a nose. You realize it's magical for the parents and you realize the power of what you do to make life a little bit better. And it's fun to watch the residents do that. It helps them," he says, adding, "I know it helped me." ■



© rolffimages - Fotolia.com

Extreme weight loss doesn't necessarily result in a sculpted body. Patients often must contend with excess skin around the face, neck, abdomen and other areas.

■ Body contouring

Comfortable in their skin

Bariatric surgery patients are turning to plastic surgeons to help them deal with the aftermath of extreme weight loss.

BY ADRIENNE FOLEY

Patients who have lost a massive amount of weight following bariatric surgery often face a new problem: what to do about sagging skin that not only is unsightly but also can lead to problems such as skin rashes, infection, and ulcers, not to mention difficulty fitting into clothes and exercising.

Dealing with excess skin has spawned new work for plastic surgeons: body contouring, essentially removing skin and tightening and reshaping areas of the body that are sagging. Given the growing number of people who are having bariatric surgery, body contouring is a growth business for plastic surgeons. "Each year, we are seeing an increase in post-bariatric body contouring surgery," says Umar Choudry, M.D., assistant professor of plastic surgery at the University of Minnesota. According to the American Society of Plastic Surgeons, the number of such procedures performed in the United States increased by 6 percent from

2009 to 2010 alone.

Surgeons in other parts of the world are noting a similar trend. A study conducted by researchers at the Medical University of Vienna published in *Obesity Surgery* in January 2012 showed there is a high demand for body contouring among patients who have undergone bariatric procedures. Of the study participants who underwent gastric bypass surgery between 2003 and 2009, 74 percent desired a body-contouring procedure afterward and 21 percent had already undergone such procedures.

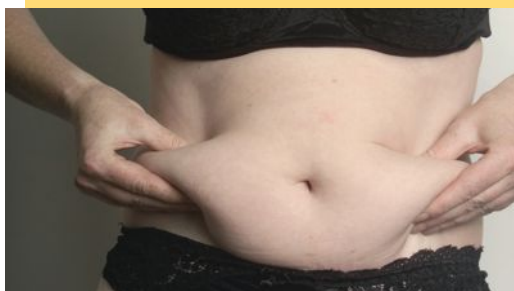The growing demand has prompted some plastic surgeons to focus their practices on this work, and some bariatric centers such as the ones at the University of Minnesota Medical Center, Fairview, Abbott Northwestern, United and Unity hospitals to develop close working relationships with plastic surgeons. In

addition, fellowship programs in post-bariatric body contouring surgery are now offered at the University of Pittsburgh, the Cleveland Clinic and other institutions.

“A number [of patients] are referred to us by bariatric centers, but quite often many come to us directly after learning about body contouring from nutritionists, support groups, social workers, or other patients who have had it done,” says Daniel Cantwell, D.O., a board-certified plastic surgeon at Allina Medical Clinic—Plastic and Reconstructive Surgery Associates in Coon Rapids.

Sculpting the body

Body contouring can be performed on a number of areas. A circumferential or lower body lift corrects sagging skin of the abdomen, buttocks, groin and outer thighs. A mastopexy, or breast lift, reshapes flat and sagging breasts, sometimes with the use of an implant for added volume. A brachioplasty, or arm lift, involves removal of the excess skin and tightening of the upper arms. A thigh lift corrects the drooping skin of the inner thighs. All are considered major surgeries and are performed in a hospi-



In some cases, excess skin can be donated to tissue banks.

© Karen Struthers - Fotolia.com

What happens to leftover skin?

Body contouring surgery after massive weight loss can result in the removal of anywhere between two and 25 pounds of skin, which begs the question, Is there any use for that excess skin?

Unfortunately, not much. Using donated skin tissue for skin grafts is really not an option because of the risk of infection. In addition, the excess skin is often undesirable because it has lost its elasticity, says Daniel Cantwell, D.O., a board-certified plastic surgeon at AMC-Plastic and Reconstructive Surgery Associates in Coon Rapids. Patients can donate extra skin for research purposes, says Umar Choudry, M.D., assistant professor of plastic surgery at the University of Minnesota. Skin also can be donated to tissue banks such as the Musculoskeletal Transplant Foundation or Tissue Banks International for the production of skin substitutes, he says.—A.F.

Do you trust your live operator to make decisions for you?

Protect yourself by having all calls recorded.



Designed by a team of physicians, software engineers, and telecommunication experts, MedXCom is a fully-automated communications system.

No more ...

- Calls from your service when you aren't on call
- He said/She said arguments with your patients
- Hassles from live operators
- Taking calls without hearing the true story
- Not knowing who is calling you



Step into the next generation of highly secure, HIPAA-compliant patient and physician communications:

Start using MedXCom today!

Special pricing for Minnesota Medical Association Members. 6 month free trial period. Sign up at www.medxcom.com.



Become a MedXCom user today! Call 1-855-MED-XCALL or visit medxcom.com.

tal or surgery center, and each one can take two to four hours to complete. The length of scars and number of sutures are relative to the amount of tissue removed and the location.

The Viennese study showed that abdominoplasties are the most common (59 percent) procedures performed on bariatric patients. Both Choudry and Cantwell say abdominoplasty is the most common procedure performed on their bariatric patients, followed by contouring of the skin of the upper arms, breasts, and inner and outer thighs.

Whole-body contouring often requires a series of surgeries that can take as long as two years to complete. The process starts with a detailed consultation with the plastic surgeon, who then develops a surgical plan. For example, if a patient were to undergo whole-body contouring, the first stage could be the circumferential body lift, followed by the arm lift and inner thigh lift, then the breast lift, and finally the neck lift and facial rejuvenation, according to Choudry. Usually, the procedures are staged to give the patient time to recover (about six weeks, depending on the procedure). “It is advisable to have a maximum of six hours of surgery at one sitting, and each stage is usually performed six months apart,” he says.

Good skin is key

According to the American Society for Plastic Surgeons, adults of any age whose weight loss has stabilized, who do not have medical conditions that can impair healing or increase the risks

of surgery, who do not smoke, and who are committed to leading a healthy lifestyle by eating properly and exercising are good candidates for body contouring procedures.

Patients also must have realistic expectations in terms of aesthetic outcomes. “We want patients to have good outcomes that are long-lasting, not only from a cosmetic standpoint but also from a health standpoint,” Cantwell says. He adds that there have been times when he’s had to turn patients away. “Just like with any doctor-patient relationship, we have to have that conversation where we tell them we don’t think they’ll have a good outcome.” Choudry refers patients to a psychologist if he feels they may have issues that could adversely affect their outcome.

The biggest variable in whether a patient will have a good result, however, is the quality of their skin, and that quality can decrease with age. “After massive weight loss, patients are prone to developing overhanging skin folds because their skin is inelastic and does not retract all the way back, analogous to an overstretched rubber band,” Choudry says. “The older the patient, the less elastic the skin and, therefore, the more the redundancy of skin.”

As with any major surgery, body contouring has risks. “The most common complications are wound breakdown, fluid collections and minor infections,” Choudry says. Serious complications such as major infections, major tissue loss and blood clots are rare, but they do happen.

However, the benefit to the patient usually far outweighs those downsides. “This surgery allows patients to no longer have rashes or abscesses due to excess skin, to find clothes that fit their body, and to exercise and maintain that healthy weight,” Cantwell says.

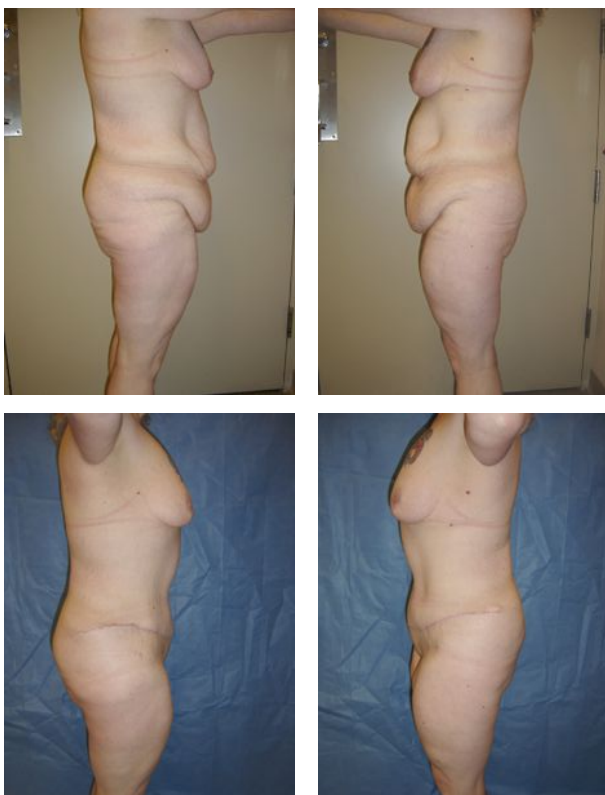The cost conundrum

Most patients who want body contouring procedures have to be prepared to pay for them out of pocket. Choudry says these surgeries, on average, cost between \$5,000 and \$10,000 per procedure.

More times than not, insurance companies deem them cosmetic rather than medically necessary. In order to determine whether a procedure is purely cosmetic, photographs are taken and submitted, along with the surgeon’s report, to the patient’s insurance company for review prior to surgery.

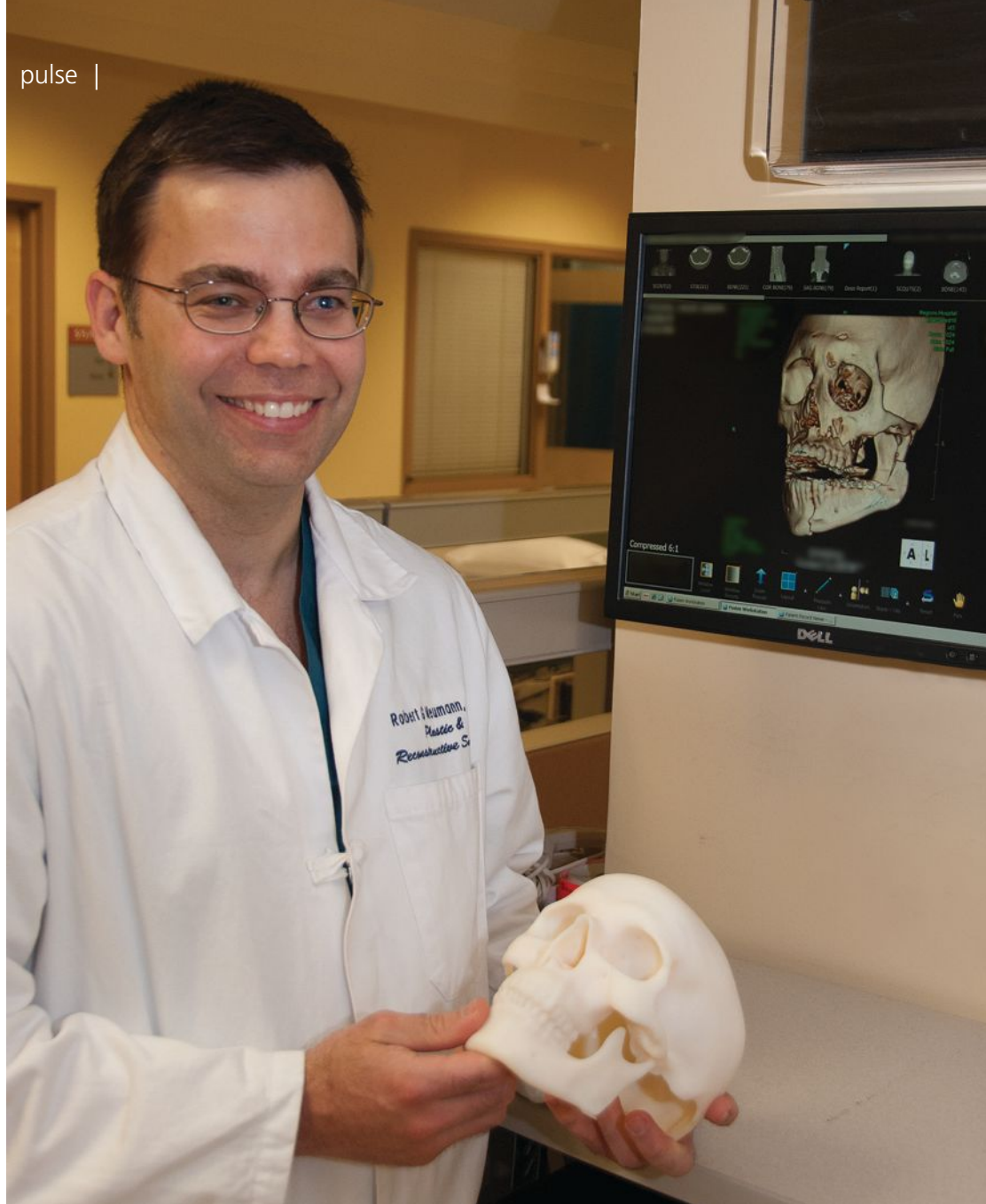“What is deemed as medical necessity varies among insurance companies, and there is no uniform definition,” Choudry says, adding that most insurance companies still deny most requests.

Having to pay out of pocket isn’t stopping patients who’ve come so far in terms of improving their health from going through with these procedures. Says Cantwell: “In my view, body contouring surgery essentially completes the weight-loss journey for these patients.” ■



Photos courtesy of Umar Choudry

Before and after photos of a patient who underwent abdominoplasty after losing 100 lbs.



Robert Neumann, M.D., took a traditional path to plastic surgery. He completed a residency in general surgery at Washington University in St. Louis before being accepted into the University of Minnesota's plastic surgery residency program.

Photo by Kathryn Forss

■ Plastic surgery training

The making of a plastic surgeon

There are now two routes to becoming a plastic surgeon.

| BY KIM KISER

Robert Neumann, M.D., didn't plan to become a plastic surgeon. But his future started to become clear during a general surgery residency at Washington University in St. Louis. One night, a man whose face had been crushed when someone threw a brick through his car window was brought in to the trauma unit at the hospital where he was training. The next morning, Neu-

mann assisted with the arduous process of reconstructing the man's face. "They had to do bone reconstruction and then soft-tissue reconstruction, and they had to use an approach within the mouth. I realized at that point that ... they were combining techniques of all the different specialties—vascular surgery, orthopedic surgery, minimally invasive surgery—that I thought were neat individually, but I had

never seen them combined in that way."

It was while assisting the same group of surgeons as they performed microvascular anastomosis on a patient having breast reconstruction that Neumann knew he had found his calling. After completing his general surgery residency, Neumann applied to the University of Minnesota's plastic and reconstructive surgery residency program, where he is now finishing

The right stuff

It takes more than technical skills to be a good plastic surgeon.

In May, plastic and reconstructive surgery residency program directors were busy interviewing candidates who will begin their training this summer. Bruce Cunningham, M.D., residency program director at the University of Minnesota, and a group of faculty members interviewed nine people for two slots. Samir Mardini, M.D., who directs Mayo Clinic's program, led a team that talked to 35 people vying for four positions. We asked them, along with Matthew Sherrill, M.D., who is nearing the end of his residency at the university, what, other than technical skills, the "must haves" are for a good plastic surgeon. Here's what they said:

Patience. "Reconstruction is a time course," Sherrill says. "You need time for the tissues to settle down, for the scars to heal, for the end results to show up." With hand surgery, for example, surgery is just the first step in the recovery process. "The outcomes are really long-term."

A creative mind. "Plastic surgeons have to deal with soft-tissue deficits or cancer operations in which they have to figure out how to reconstruct the person," Sherrill says. "We have an armamentarium of treatment options—a reconstructive ladder in which you go from less invasive to very invasive. If one approach doesn't work, there are more complex solutions to fall back on."

Love of variety. "You could be amputating a toe one day, doing craniofacial remodeling on a 2-year-old the next. You could be doing a chest-wall reconstruction and then a cleft lip repair. It's a very broad field," Mardini says. And you get to operate on all body parts—the head and neck, the abdominal wall, the leg, Sherrill says. "You're dealing with blood vessels, nerves, muscles, skin."

A team focus. "You have to have the mindset of collaboration," Mardini says. "Yesterday, I worked with a thoracic surgeon to reconstruct a chest wall deficit. I've worked with a neurosurgeon to reshape a skull, with general surgeons removing a big hernia—we worked with them to close the [tissue] deficit. We work with orthopedic surgeons on bone fractures and exposure."

Good communication skills. Patients having aesthetic procedures may have unrealistic expectations, and you may never be able to satisfy them, Mardini says. "I've seen leaders in the field show results of patients and then show the letters they received afterward telling them 'You've messed up my life to the point where I can't leave the house because of what you've done.'" Mardini says plastic surgeons have to make sure they understand what the patient wants and give that person a realistic idea of what he or she can expect, especially in cases where a procedure will alter a person's appearance. He says they sometimes include a psychiatrist on the team to help a patient set expectations.

A desire to help. When interviewing residency candidates, Cunningham and his colleagues often look for those physicians who've done medical missions in third-world countries. "Anyone who starts talking about the thrill of seeing lives changed is someone we're interested in," he says. "That's the core of what we do."

How they got there



Samir Mardini, M.D.

Trained at Georgetown University and did a fellowship in craniofacial surgery and microsurgery at Chang Gung Hospital in Taiwan. He has since established a partnership between Mayo Clinic and researchers in Taiwan. Faculty from both institutions host an international meeting each year to discuss problems in reconstructive and craniofacial surgery. This year's meeting was held in Rochester.



Matthew Sherrill, M.D.

Became interested in plastic surgery during a rotation at a Veterans' Affairs hospital while in medical school at Texas A&M University. What he found interesting was the different ways plastic surgeons tackled problems. After medical school, Sherrill, who was in the military, worked as a flight surgeon before starting a residency in general surgery at the University of North Carolina and then coming to the University of Minnesota.



Bruce Cunningham, M.D.

The son of a general surgeon, Cunningham initially thought about becoming a psychiatrist. But after working as a scrub tech during undergraduate and medical school, he saw plastic surgeons do "fascinating things" and decided to go that route. As a plastic surgeon doing cosmetic work, "you are a psychiatrist," he says.

his second year. He plans one day to work in an academic setting.

Different routes

Neumann's path to plastic surgery is a common one. The majority of plastic surgeons practicing today got their start in general surgery, says Bruce Cunningham, M.D., who directs the University of Minnesota's plastic and reconstructive

Future plastic surgeons then went on to a second residency in plastic and reconstructive surgery, where they learned techniques such as hand surgery, breast surgery, microsurgery, burn reconstruction and tissue transfer. Training lasted two or three years. Just last year, the Accreditation Council for Graduate Medical Education's (ACGME) residency review committee began requiring that all plastic

In 2008, the ACGME review committee, the American Board of Plastic Surgery (ABPS) and the Association of Academic Chairmen in Plastic Surgery sanctioned a pathway that enables graduating medical students to go directly into plastic surgery residency.

Called the integrated pathway, residents spend six years, rather than eight, in training. During their first two years, they become grounded in general surgery principles, doing rotations in general surgery, orthopedic surgery, ENT surgery, and plastic surgery. They don't rotate on services such as transplant or cardiovascular or colorectal surgery, which are typical components of general surgery programs. In their third year, they also do rotations in pediatric surgery, maxillofacial surgery, neurosurgery and dermatology. "You do rotations to get the skills you can carry forward into plastic surgical practice," says Cunningham, who chaired the ABPS when discussions about creating the path-

Currently, about half the plastic surgery residency slots are for those seeking the integrated pathway.

surgery residency program. Others came out of otolaryngology, orthopedic surgery, oral and maxillofacial surgery, urology or neurosurgery residency programs. "There were a couple of pathways, but all went through basic training in another specialty," he says.

and reconstructive surgery residencies be three years, acknowledging the fact that the field has become so broad, Cunningham says. Both the University of Minnesota and Mayo Clinic have always had three-year programs.



SEE YOU AT **MMA'S 2012 Annual Gathering**

Plan to attend the MMA's Annual Meeting in Minneapolis.
The event is an opportunity for physicians in all specialties to come together to network, discuss policy and learn. It includes the meeting of the MMA House of Delegates, which sets policy for the MMA.

WHO: All physicians, residents, medical students
WHEN: Friday and Saturday September 14-15
WHERE: Minneapolis Marriott City Center

WATCH FOR MORE INFORMATION

SPECIAL KEYNOTE ADDRESS
by Joe Bujak, M.D.
Dr. Bujak, author of Inside the Physician Mind: Finding Common Ground with Doctors, is a nationally known expert on physician communication.

Find out more at www.mnmed.org/AnnualMeeting

way were taking place. After the third year, residents focus entirely on plastic surgery.

Pros and cons

Currently, about half of the plastic surgery residency slots nationwide are for those seeking the integrated pathway, according to ACGME figures. “The numbers increase every year,” Cunningham says. Both the University of Minnesota and Mayo are looking at adding an integrated pathway to their offerings.

But the establishment of the new pathway begs the question of whether cutting two years off the training process is a good idea. “There are advantages and disadvantages to each,” says Samir Mardini, M.D., who directs the residency program at Mayo Clinic. Integrated programs focus more time on plastic surgery early in the residency. “Trainees learn the thought process and techniques in the junior years of training,” he says. “The two extra years spent in general surgery are of course beneficial; however, those two years could be spent subspecializing in a field within plastic surgery.”

And Cunningham says, “People coming out of medical school aren’t as mature and experienced as those who have finished a general surgery residency. They won’t have the technical skill set that someone who has been doing procedures for four years has, and that will be more of a challenge for educators.”

Matthew Sherrill, M.D., who came out of a general surgery residency and is currently in the third year of the University of Minnesota’s program, says he believes being a general surgeon has made him a better plastic surgeon. “As a first- or second-year member of the team, you don’t make a lot of decisions. But during your fourth and fifth year of general surgery, the staff physicians usually put a lot of onus on you to manage patients and take charge of the service. You’re responsible for the entire team. You become comfortable with managing patients and with managing and being efficient in the OR,” he says.

On the other hand, the integrated pathway is a guaranteed point of entry to the field. Cunningham says most people who go into plastic surgery know when they are medical students that they want to do a plastic surgery residency. “They don’t want to go into general surgery and take the risk of maybe not getting into a plastic surgery program in four years,” he says. “Also, the six-year program takes years off the total training, which is probably good for the medical economy.” And Cunningham, who last month interviewed candidates for the university’s two residency slots, noticed that the most talented candidates appear to be gravitating toward integrated programs.

Whether they take a traditional or integrated path, most plastic surgeons will continue their training after residency. “Plastic surgery has become so broad in its scope and so much more technically challenging that a lot of people will have to do a fellowship if they want to focus on an academic career in a specific area,” Cunningham says. ■

Dr. John Allan Ness

Triple Board Certified* in
Plastic Surgery, Facial
Plastic Surgery &
Otolaryngology with
over 14 years of plastic
surgery experience.

Our staff has over
50 combined
years in caring for
plastic surgery
patients.

We specialize in
helping women
reclaim their
bodies and their
confidence after
pregnancy.

We are your
experts
in plastic and
cosmetic surgery.

ness

PLASTIC SURGERY

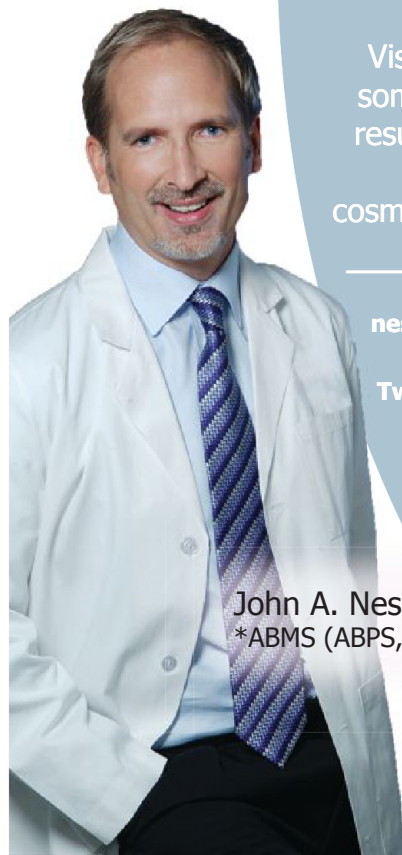
Improving You.

Visit us online to see
some of our beautiful
results or call us for a
complimentary
cosmetic consultation.

nessplasticsurgery.com

763.559.4500

Twin Cities | St. Cloud



John A. Ness, M.D., F.A.C.S.
*ABMS (ABPS, ABO), ABFPRS





Reshaping lives

Breast reconstruction
is now integral to **cancer care**

by J. TROUT LOWEN

For years,
breast cancer treatment was focused almost entirely, and by necessity, on patient survival. But with early detection and more effective treatment, many women and their physicians are thinking not only about survival but also about quality of life. Increasingly, for women who have had a mastectomy, quality of life includes breast reconstruction surgery.

Once an afterthought to treatment, breast reconstruction has become an integral part of cancer care. At breast centers throughout Minnesota patients are now asked about reconstruction as early as their first conversation about mastectomy, and plastic and reconstructive surgeons have become part of multidisciplinary teams, working alongside oncologists, general surgeons, radiation oncologists, pathologists and nurse navigators.

“The biggest change for plastic surgeons is that we’ve been invited to the party,” says Mark Migliori, M.D., a specialist in breast reconstruction at the Piper Breast Center at Abbott Northwestern Hospital in Minneapolis. “We’ve been invited to help improve outcomes, and there’s recognition that the outcome is not just a survival rate of five years. The outcome is about productivity, it’s about sexuality, it’s about personal relationships and it’s about satisfaction.”

Decisions, decisions

Every year, more than a quarter million women in the United States are diagnosed with breast cancer. Some 37 percent of those with ductal carcinoma in situ (stage 0) or invasive breast cancer (stages I to III) will have one or both breasts removed. And as genetic screening has improved, the number of preventive or risk-reducing mastectomies among younger women with the BRCA genetic deformity has been rising, according to a series of articles published in 2009 in the *Annals of Surgical Oncology*.

With few exceptions, most women who undergo mastectomy and are otherwise healthy are eligible for some type of breast reconstruction, and the number of women choosing reconstruction has been increasing even as the number of mastectomies has fallen. According to the American Society of Plastic Surgeons, 96,000 breast reconstruction procedures were performed in the United States in 2011, a 3 percent increase over 2010.

The reasons women choose breast reconstruction are varied. Many do it to signify the end of treatment, to put the cancer phase of their life behind them and “to feel like myself” again, says Darlene Leqve, R.N., a nurse educator for the plastic surgery division at Mayo Clinic. Leqve explains the types of reconstruction procedures—those that use implants and those that use autologous tissue—and the process. She says her goal is to help empower each patient to make the decision that is right for her. Depending on the patient’s diagnosis, overall health and personal concerns, she can choose immediate, delayed-immediate or delayed reconstruction. Immediate reconstruction happens at the time of mastectomy surgery. Delayed-immediate reconstruction is a two-stage process used if the patient is likely to need radiation therapy. Delayed reconstruction often starts after other treatment is completed and

can be performed even years after mastectomy.

Research has shown that women who choose immediate reconstruction tend to experience greater well-being and benefit from improved body image and greater self esteem than women who delay reconstruction. Those who work closely with patients, however, know that each woman responds to mastectomy differently. “For some women, it’s a comfort knowing that when they go into that operating room to have a breast or breasts removed that the process of reconstruction can begin immediately,” Leque says. It’s such an individual journey,” she says, noting that it requires the patient sitting down and asking herself questions about what she needs at this point in her life.

Although the number of women choosing reconstruction is increas-

who pays?

The Women’s Health and Cancer Rights Act, which was signed into law in 1998, says mastectomy benefits must cover

- reconstruction of the breast on which the mastectomy was performed,
- surgery and reconstruction of the other breast to produce a symmetrical or balanced appearance,
- the prostheses (or breast implant) and
- any physical complications at all stages of mastectomy, including lymphedema.

The law applies to group health plans, health insurance companies and HMOs, if the plans or coverage provide medical and surgical benefits for mastectomy.

ing overall, fewer than one-third of all women and just half of women under the age of 50 opted for immediate reconstruction in 2010, according to a study by Dawn Hershman, M.D., associate professor of medicine and epidemiology at Columbia University Medical Center in New York. Hershman’s study, which looked at insurance records for 106,988 mastectomy patients between 2000 and 2010, found that while rates for immediate reconstruction increased from 15 percent to 33 percent during that time, just 22.6 percent of mastectomy patients in 2010 had immediate reconstruction. Age and insurance status were key factors in determining which women had the procedure. Women who had commercial insurance and women younger than 50 years of age were more likely to have it. Older women, African-American women, women on Medicare or Medicaid, and women treated at rural or at nonteaching hospitals were less likely to get immediate reconstruction.

The primary reason patients choose not to undergo immediate reconstruction is fear it will make it more difficult to detect a cancer recurrence. Although some women do experience a recurrence after mastectomy, multiple studies have shown that reconstruction does not delay detection of cancer.

In all cases, physician input is critical to women contemplating breast reconstruction. A study of 181 mastectomy patients published in *Annals of Surgical Oncology* in 2004, found patients regarded their surgeon’s advice as the most important factor in their decision about reconstruction. And those who chose reconstruction rated their surgeon’s advice as more influential than those who did not choose reconstruction.

Approaches to reconstruction

Diagnosis, overall health and patient preference all factor into which type of reconstruction procedure is appropriate for an individual patient. With implant-based reconstruction, the surgeon uses a silicone gel or saline implant to recreate the breast mound. With autologous reconstruction, he or she remakes the breast mound using skin, tissue and muscle from the patient’s abdomen or another area of the body. Autologous procedures include TRAM (transverse rectus abdominis muscle) flap, which uses muscle and tissue from the lower abdomen; latissimus dorsi flap, which uses tissue and muscle from the upper back; gluteal free flap, which uses tissue from the buttocks; and inner thigh or TUG flap, which uses muscle and tissue from the inner thigh and buttocks.

Both implant and autologous reconstruction can be done immediately or later. Factors such as smoking, breast size, physical condition, availability of additional tissue and stage of breast cancer can affect the type and timing of reconstructive surgery. “Every patient is dif-

ferent,” says Mayo plastic surgeon Paul Petty, M.D. “Every breast is different. If you have a D cup, that’s a very different patient than if you have an A cup.”

According to the American Society of Plastic Surgeons, more than two-thirds of all breast reconstruction procedures are done using a tissue expander and implant. The procedure involves placing a temporary expansion device on the chest wall underneath the pectoralis muscle. The expander is gradually filled with saline over several weeks to stretch the muscle and skin to create a breast pocket. When the desired size is achieved, the expander is removed and replaced with a soft implant. Most often, expanders are placed at the time of mastectomy.

Two recent developments have made implant-based reconstruction more appealing for some women: nipple- and skin-sparing mastectomy and the use of acellular dermal matrix. Many women who have early-stage cancer with no involvement near the nipple are now candidates for nipple-sparing mastectomy, a procedure in which the breast tissue is removed but the nipple and areola and much of the breast skin are left in place. Nipple-sparing mastectomies result in better aesthetic outcomes, Migliori says, because the nipple is one of the hardest things to reconstruct.

Perhaps the biggest development over the past three years is the use of dermal substitutes, made from human or porcine skin from which the cells have been removed, to create an “internal bra” to support an implant. The flexible acellular dermal matrix patch is attached to the muscle fascia of the chest wall, allowing surgeons to recreate the inframammary fold under the breast. It’s then attached to the lower edge of the pectoralis muscle to create an internal bra that supports the expander or implant and protects the skin envelope.

The benefits of using a dermal substitute include not having to stretch the muscle to accommodate the implant, which takes time and can be painful; being able to create a larger breast mound at the time of surgery; and less risk of capsular contraction, a hardening of the scar tissue around the implant that squeezes and distorts the shape of the breast. The use of dermal substitutes has cut the incidence of capsular contracture by 90 percent, Mayo’s Petty estimates. And in some cases, with use of dermal substitutes and nipple-sparing mastectomy, the reconstructed breast can look “as good or better than it did prior to the mastectomy,” he says.

The use of a dermal substitute also allows surgeons to perform a direct-to-implant one-step procedure in some women. “Thirty to 40 percent of the time we can go right to the soft implant,” Migliori says. Although use of these products (known by the trade names AlloDerm, DermaMatrix, Tutoplast and Strattice) is becoming widespread, some physicians are concerned they might increase the risk of infection (which hasn’t been the case) and that they increase costs (which can be as much as \$20,000 for bilateral reconstruction). But surgeons who use them are enthusiastic. “I didn’t move into the use of these materials lightly, but I am wholeheartedly there now,” Petty says. “If I didn’t think there was a quantum difference between what I was able to achieve before and

after, I would have very quickly stopped using it.”

Use of dermal substitutes also is creating better outcomes for women in their 20s and 30s. Younger women tend to have tighter musculature and breast skin than older women and women who have had children, which is more difficult to stretch using an expander.

Implants are not the answer for every patient, however. Some women don’t like the idea of having a foreign or synthetic substance in their bodies. And implants aren’t necessarily the best choice for women who need postmastectomy radiation therapy, which causes skin and fat to tighten and shrink. “Radiation is the gift that keeps on giving—and not in a good way,” says Sue-Mi Tuttle, M.D., a HealthPartners plastic surgeon who works at Regions Hospital in St. Paul. “Once you radiate something, it continues to get fibrotic, scar and shrink.”

For such women, using a tissue flap taken from another part of the body may be a better option. The most common autologous flap procedures are the TRAM flap and the latissimus dorsi flap.

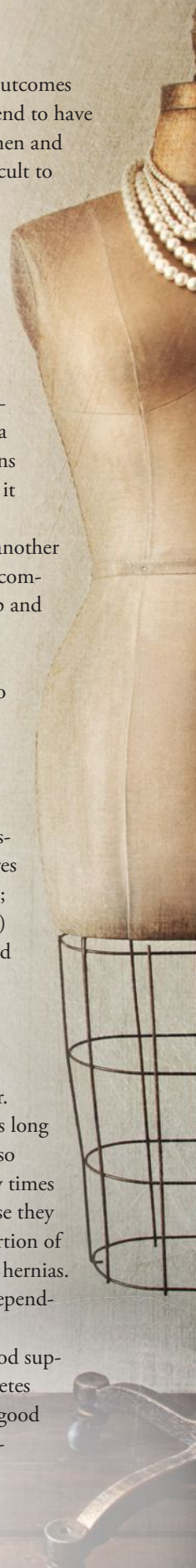
To perform the TRAM flap, the surgeon may either leave the muscle and tissue partially attached to its original blood supply and tunnel it under the skin from the abdomen to the breast area (pedicle flap) or use microsurgical techniques to completely remove a flap of skin, muscle, fat and blood vessels from the abdomen and then reattach it to blood vessels in the chest (free flap). Three kinds of procedures are used in the latter approach: the free TRAM flap; the DIEP (deep inferior epigastric artery perforator) flap, which uses skin and fat from the abdomen; and the SIEA (superficial inferior epigastric artery) flap, which also uses fat and skin from the abdomen.

Risks and benefits

Flap procedures can take a toll on patients, however. Bilateral mastectomy and reconstruction can take as long as 12 hours. Patients undergoing flap procedures also experience longer hospital stays and longer recovery times than those who undergo implant procedures because they have two wound sites. In addition, removal of a portion of abdominal muscle can cause abdominal bulges and hernias. And there is up to a 4 percent risk of flap failure, depending on the procedure.

Because the transplanted tissue needs a good blood supply, women who smoke and women who have diabetes or vascular or connective tissue disease may not be good candidates for flap reconstruction. And after surgeries that remove a portion of the abdominal muscle, women can develop abdominal weakness that can exacerbate back problems.

Implant reconstruction has risks as well. Im-



a future for fat

One of the newest developments in breast augmentation, fat grafting, may have potential for breast reconstruction following mastectomy. Fat grafting, which makes use of fat from a patient's abdomen, buttocks, or other areas of the body to create breast bulk, has been approved by the Food and Drug Administration for breast augmentation procedures but not yet for breast reconstruction.

Miami plastic surgeon Roger Kouri, M.D., who is considered the leading proponent of fat grafting, has created an external bra-like suction device that serves as an external tissue expander. Women undergoing breast augmentation wear the device up to 10 hours per day for several weeks to stretch the breast skin. The cavity is then injected with fat liposuctioned from other areas of the patient's body. The process is repeated until the desired breast size is achieved.

After observing the procedure in Florida, St. Paul plastic surgeon Sue-Mi Tuttle, M.D., says she and her partners at Regions Hospital are excited by the possibilities. "The beautiful thing is, you don't use a knife and there's no recovery period like you have with a DIEP or TRAM flap," she says. "And it's your own tissue."

Other surgeons are skeptical that mastectomy patients will be interested in a procedure that is so cumbersome and lengthy. Patient testimonials and Kouri's own website suggest patients have to be "dedicated and determined" to complete the procedure.

"I think most patients just don't want that kind of process," says Bruce Cunningham, M.D., a professor of plastic and reconstructive surgery at the University of Minnesota. "They want to get the deal done and have it done as smoothly as they can."

Fat grafting does have potential therapeutic benefit for women who have radiation after mastectomy, Cunningham says. The stem cells harvested in fat liposuctioned from the abdomen may stimulate blood ingrowth.—J.T.L.

plants carry a slightly higher risk of infection than autologous tissue. Patients with implants also are at risk for capsular contraction. In addition, implants sometimes rupture and need to be replaced, a consideration for younger women who may live with their implants for decades. After seven years, there is a 3 to 4 percent chance of rupture with a silicone gel implant and a 7 to 8 percent chance of rupture with a saline implant.

One issue that is no longer a concern, surgeons say, is the safety of silicone gel implants, which were banned by the Food and Drug Administration in 1992 because of concern that ruptured implants were causing health problems. After extensive testing, the FDA lifted the ban on silicone-gel implants in 2006. Most women now get silicone-gel implants because they're more comfortable than saline implants, and they produce a better aesthetic result.

Part of the team

As plastic surgeons become more involved in the early and ongoing care of breast cancer patients, they're having an impact on other aspects of care. For instance, at the Piper Breast Center, surgeons, oncologists, plastic surgeons and other care team member meet every Monday morning to discuss new cases.

Decisions that might once have been made by one physician are now discussed by the entire team. The result is better care coordination and better outcomes, Migliori says. "We're getting much more thoughtful about trying to anticipate the potentials for a patient going forward and using that knowledge to make really good choices," he explains. "Where the general surgeons are going to make their biopsy incisions, where the radiologist will do the needle biopsies, all that stuff is now factored into the end result."

As part of the breast care team, plastic surgeons also are learning more about the cancer process, which allows them to provide better and more consistent patient care. "We're not missing things. Things aren't falling through the cracks," Migliori says. And because he sees his patients annually for years after surgery, he is learning things that help him improve his work as well. "When I started this job, it was very much the technical aspect of how do you make a breast look like the other breast. Then I realized that that is just a small part of what we're really trying to do," he says. "I like to tell my patients that ultimately what I'm trying to do is get you to the point where you think less about your cancer and less about your breast." **MM**

J. Trout Lowen is a freelance writer in Minneapolis.



MINNESOTA
MEDICAL
ASSOCIATION

THE PHYSICIAN ADVOCATE

The MMA's monthly report on policy, people and politics

LEGISLATIVE REVIEW

Revising and improving previous work is theme for 2012

For the first time since 2007, lawmakers walked into the state Capitol in January without the specter of a budget deficit hanging over their heads. For that reason, observers, including the MMA, were optimistic that lawmakers could make progress on a number of issues related to health care.

As it turned out, the 2012 legislative session became more about course correcting—revising and improving past legislation, and rendering it more physician friendly.

“Because of the budget surplus, there were no crisis issues that had to be addressed,” notes Dave Renner, MMA director of state and federal legislation. “The Legislature did not feel a need to pass any particular bill.”

Although lawmakers did restore some funding to the Health and Human Services budget, they missed out on several opportunities to help physicians and their practices—and health care in general. “For example, funding for our residency training sites was drastically slashed in 2011,” Renner points out. “We had an opportunity to replace some of those funds this year but failed to do so.”

(continued on next page)



THE **HITS**



THE **MISSES**



THE **VETOES**



Photo by Dan Hauser

LEGISLATIVE REVIEW

(continued from previous page)

Here the *Physician Advocate* examines some of the critical hits, misses and vetoes of the 2012 session.

THE HITS

More background provided to patients

Information regarding malpractice judgments, criminal convictions and actions by other licensing boards will now be available to Minnesotans thanks to legislation passed this session.

The health licensing disclosure bill (often referred to as the BMP bill) was the result of an investigative report in the *Minneapolis Star Tribune* that called into question the Board of Medical Practice's lack of transparency regarding physician disciplinary actions.

"Throughout the discussion of the BMP and the licensing board disclosure bill, the MMA focused on how to ensure that patients get information that will be helpful to them when choosing a health care provider," Renner says. "We want to make sure that the physicians and other health care providers who practice in our state meet the highest standard possible for providing care."



The emphasis on "helpful" information is what compelled the MMA to push for removal of language that called for including malpractice settlement information in the online data available to consumers. "We've maintained that settlements are not an accurate tool to gauge the quality of a physician," Renner says.

The disclosure bill also calls for studies:

- To develop recommendations for a standardized approach to criminal background checks, which may include fingerprinting;
- Of how the BMP implements the Medical Practice Act (to be conducted by the Office of the Legislative Auditor);
- Of whether the Medical Practice Act provides protections and transparency for the public (to be conducted by the Commissioner of Health). This effort will involve an advisory committee that will include two MMA appointments.

The new BMP information will be available online starting July 1, 2013. Only malpractice judgments, criminal convictions and actions by other licensing boards occurring on or after that date will be posted.

Provider peer grouping reforms

Hospitals and clinics will now have adequate time to review information on cost and quality before it is released to the public, thanks to revised provider peer grouping (PPG) legislation.

"The new provider peer grouping legislation creates more realistic deadlines for public reports and provides an opportunity for clinics and hospitals to verify the accuracy of their reports," Renner says.

It also includes language creating a committee to advise the health commissioner on patient attribution, quality scoring and cost-scoring methodologies. In addition, the bill streamlines the appeals mechanisms for hospitals and clinics that have concerns about their reports.

"The passage of the PPG bill will be felt when the Department of Health begins developing and releasing cost and quality reports on specific clinics," Renner says. "The law shifts the emphasis of these reports away from simply providing tools for health coverage purchasers to providing information to hospitals and clinics to use for quality improvement. This is the greatest value of PPG."

Supplemental funding for Health and Human Services

During last year's session, lawmakers cut \$1.3 billion from the state's Health and Human Services budget, so the fact that \$18 million was re-allocated this year can be considered a victory, albeit a small one.

The Legislature restored funding to several programs and called for a number of studies. Here's a breakdown.

“
The new
provider peer-grouping
legislation creates
more realistic
deadlines for
public reports.
”

– Dave Renner, MMA director of
state and federal legislation

The Health and Human Services bill allocated:

- \$5.9 million to personal care attendants;
- \$4.9 million to reinstate coverage for dialysis and cancer treatment for Emergency Medical Assistance patients;
- \$1.1 million for audits of the Prepaid Medical Assistance Program (PMAP) beginning in 2014 (then occurring every other year);
- \$235,000 for a study of the value of managed care in the state's public programs;
- \$200,000 for an autism study by the University of Minnesota.

The bill called for studies of:

- The design of the Emergency Medical Assistance program;
- PMAP satisfaction, access and ability to produce high-quality outcomes;
- The repeal of Rule 101, which requires health care providers' participation in state public health care programs as a condition of participation in the state employee health plans;
- Capacity of radiation therapy treatment facilities throughout the state;
- Methods to better protect patient records from unauthorized access and release, and mechanisms to inform patients if their records are inappropriately accessed or released;
- Cost-sharing structures and requirements for patients.

Along with funding and the call for studies, the bill expanded civil penalties for illegal release of patient records to include unauthorized access of patient records.

The bill did not:

- Include any new funding for the Medical Education Research Costs fund;
- Restore last year's 3 percent cut to physicians treating patients under fee-for-service Medical Assistance;
- Fund a for-profit HMO study or transfer of HMO regulation

from the Department of Health to the Department of Commerce;

- Fund a health insurance mandate study.

Newborn screening to continue, process modified

The Minnesota Department of Health can continue its newborn screening program thanks to legislation that establishes a "standard retention period" for blood spots of 71 days (and two years for test results) before they are destroyed. Practitioners use these blood spots to screen for more than 50 genetic and congenital defects.

The legislation also allows parents to give consent for long-term storage (up to 18 years) of the spots and test results and permits researchers to use the spots for development of new tests. Notably, the legislation allows the health department to use the spots within the 71-day window for test calibration and quality control, activities that were not clearly authorized by the Minnesota Supreme Court in its *Bearder* decision, which placed restrictions on the retention and use of the spots.

"Allowing the Department of Health a mechanism to keep blood spots for longer periods is key as it will enhance the development of new tests," says Eric Dick, the MMA's manager of state legislative affairs. "The MMA has been a long-time advocate of newborn screening. The process identifies approximately 100 babies a year that can be saved from death or disability through early treatment."

To address the decision's impact on the state's greater public health work, the bill provides immunity from court challenge to the Department of Health as it studies what further refinements to the law are necessary to continue its public health mission. A report to the Legislature on this is due in January 2013.

The legislation also directs the Department of Health to make information and forms about the newborn screening program available to prenatal health care providers for use with expectant parents. In addition, the department will make information and forms available to expectant parents and parents of newborns both electronically and through other avenues.

E-prescribing conformity

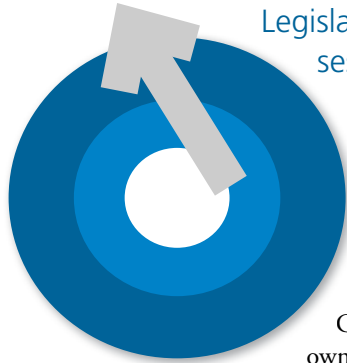In April, Gov. Mark Dayton signed into law a bill that would make Minnesota law conform to federal regulations on electronic prescribing of controlled substances, a position the MMA supports. ➔



The 2012 Legislature modified newborn screening to establish a "standard retention period" for blood spots of 71 days.

THE MISSES

Legislation that stalled during the session:



Insurance exchange

Many questions remain about establishing an insurance exchange in Minnesota after a Senate bill regarding its creation went down in defeat in late March. The federal Affordable Care Act permits states to create their own exchange by January 2013 or use the exchange that will be established by the federal government. The MMA supports creating a Minnesota exchange and will work with Gov. Dayton and legislative leaders to keep this objective moving forward.

Tobacco tax increase

A bill that would increase the tax on cigarettes and other tobacco products stalled this spring. The MMA supported this bill, believing a higher tax on cigarettes will ensure fewer kids start smoking and more adults quit.

Firearm gag rule

This bill would have prohibited health care providers from asking patients about access to firearms in their homes. The MMA opposed this bill. We believe physicians should be able to freely ask patients questions related to their safety.

Rule 101 repeal

Rule 101 requires health care providers to participate in state public health care programs as a condition of participation in the state employee health plans. The MMA supported repeal of this law.

Minor consent

This legislation called for modifying minor consent laws so that physicians could not provide any kind of treatment to minors without a parent's consent. The MMA was against this legislation and supports the current law allowing physicians to treat minors without parental consent on issues pertaining to reproductive health, mental health, and chemical and alcohol dependency.


Cosmetic laser regulation

Two competing proposals related to the use of lasers in cosmetic procedures were introduced. An MMA-supported bill would have regulated the use of laser treatment for such cosmetic procedures as removal of facial hair and skin spots. It would have required patients to have a medical exam before any procedure involving a laser. Another competing proposal would have expanded the ability of nonphysicians to use lasers for a variety of cosmetic procedures.

THE VETOES

Gov. Dayton vetoed several health-related bills. They included:

- Two abortion-related bills. One called for physicians to be physically present when a patient takes abortion-inducing drugs, and the other called for creating a new licensing requirement for clinics and other outpatient health centers in which 10 or more abortions are performed per month.
- The Health Care Compact legislation that called for Minnesota to withdraw from federal health care programs such as Medicare and Medicaid and instead receive federal block grants.
- Legislation that would have allowed for a several-week period preceding the July 4 holiday, during which aerial or exploding fireworks could be legally purchased and used in Minnesota.
- A bill that would authorize the use of new premium trust accounts to pay for health insurance premiums.



Looking ahead to 2013

This November, all 201 legislative seats will be up for grabs due to redistricting. In addition, more than 20 percent of the current crop of legislators are either retiring or running for a different office. That means there will be a lot of new faces at the Capitol come January. And they are expected to be faced with a deficit of more than \$1 billion.

EDITOR'S NOTE: *Keep track of legislative events through MMA News Now — delivered to your email box free each Thursday. To subscribe go to the MMA website and look for "MMA News Now" under the "Publications" tab.*

THE EXAMINING ROOM

The 2012 legislative session

Dominated by debates on issues such as the Vikings stadium, taxes and bonding bills, this past legislative session proved to be contentious at times. However, lawmakers were able to pass some health care-related items. The *Physician Advocate* solicited MMA members for their opinions on the recently completed session.



Marilyn Peitso, M.D.

Marilyn Peitso, M.D.


*President, Minnesota Chapter,
American Academy of Pediatrics*

Top on my “Maybe this is a good thing” list is the passage of the newborn screening amendment. This amendment clarifies and allows necessary quality monitoring and parental consent procedures in the wake of the Minnesota Supreme Court’s Bearder decision, which left Minnesota’s newborn screening program in jeopardy. It was gratifying to see bipartisan support for an approach that will maintain this important program for our state’s children and families. The accompanying genetic testing amendment allows breathing room for the Minnesota Department of Health to examine how

the Bearder decision affects its work with other genetic information.

Top on my “I’m really disappointed” list is the resistance of the Legislature to building a Minnesota insurance exchange. This is important for access to health care for families and young adults. It looks like the insurance exchange has become the victim of partisan politics to the detriment of Minnesota citizens.

I am pleased that the Legislature required that more information be provided to new mothers regarding postpartum depression, that it will study homelessness among children and appropriated funds to study autism in the Somali-American community. However, my “Penny wise pound foolish” list includes no serious attempts to improve coverage for uninsured children.



Philip Stoyke, M.D.

Philip Stoyke, M.D.

*Chair, Minnesota Academy of Family
Physicians’ legislative committee*

I would say that from a family practice/primary care perspective, very little was accomplished. Yes, the provider peer grouping law passed, which is important. There are some other small items that passed; but we came away with very little. I do not blame the MAFP or MMA or doctors in general. Rather, I think very little got done because other issues were more dominant.

One issue that needs attention is health care homes. They are proceeding but are fairly clunky and require too much paperwork to be effective and to reduce costs.

Hopefully, we can be successful next session. We know

health care homes can reduce costs and improve care, something that should have the support of both parties.

I also think that everybody is in a holding pattern with regard to further health care reforms as we are awaiting the results of the Supreme Court ruling on the Affordable Care Act as well as the outcome of the November elections.



Lyle Swenson, M.D.

Lyle Swenson, M.D.

MMA President

A bill modifying provider peer grouping was passed that will hopefully result in more accurate and helpful data on hospitals and clinics, with a more realistic timeline for the reporting of cost and quality information. A bill was passed and signed by the governor that institutes independent audits of health plans that contract with the state to manage the Prepaid Medical Assistance Program. It is hoped that this will lend much-needed transparency regarding how the state’s payments to these plans are being spent.

The Republican-controlled House and Senate offered up an alternative to the health insurance exchange concept, but it was vetoed by the governor, leaving the state with no legislative support for a Minnesota health insurance exchange.

Legislation was enacted that ends the moratorium on construction of new radiation oncology facilities in the Twin Cities beginning August 1, 2014, but requires any new facility to be owned by a hospital and not be within seven miles of an existing facility. This bill also has language affecting the information doctors must give patients regarding radiation options, and requires physicians to disclose any financial interests they have in these facilities. Finally, there was no effort to change the current phase-out of the provider tax, which is scheduled to be completely eliminated by 2020.

LEGAL UPDATE

MMA continues legal efforts in two state cases

This spring, the MMA has been actively supporting the medical profession in two cases: Dickhoff et al v. Family Practice Medical Center and Avera Marshall Medical Staff v. Avera Marshall.

In late March, the Minnesota Supreme Court granted the MMA and the Minnesota Hospital Association permission to file an amicus (“friend of the court”) brief in the Dickhoff case.

“We sought to file this brief because the Court’s decision in this case could significantly impact any physicians and hospitals involved in future medical negligence litigation,” says Karolyn Stirewalt, MMA policy counsel.

In the case, the plaintiff alleges that a delayed diagnosis of her cancer was the result of her doctor’s negligence. Her damage claims are tied to the probability of the cancer’s recurrence.

The Court will be addressing two issues: 1) what the correct standard should be for plaintiffs seeking to prove the causation element of a negligence claim, and 2) whether plaintiffs may now seek damages against physician defendants under the doctrine of “loss of chance.”

The amicus brief points out that if the Court of Appeals’ decision is affirmed, defendants in medical negligence cases will be treated differently from defendants in every other occupation who are sued for negligence, which would be unfair. The brief further argues that unless the Supreme Court overrules the Court of Appeals’ decision, a new cause of action, which Minnesota courts

have repeatedly rejected in the past, would become available to plaintiffs seeking to sue physicians and hospitals.

The case will be heard by the Minnesota Supreme Court later this year.

In the Avera Marshall case, which is underway in Lyon County District Court, the MMA along with the AMA sought to file an amicus brief but were denied. Typically, these briefs are reserved for cases at the appellate or Supreme Court level. However,

Dionne Hart, M.D., stands outside the Federal Medical Center in Rochester.



Photo by Dean Riggott

MEET A MEMBER

Dionne Hart, M.D.

| By Dan Hauser

Whenever Dionne Hart, M.D., visits a school to talk with kids about what it’s like being a doctor, the first question she inevitably hears is: “How much do you make?”

“It’s either that or ‘How long does it take to become a doctor?’” Hart says with a laugh as she describes the visits she makes to elementary schools on behalf of the Doctors Back to School Program (DBTS), which was founded by AMA members. Since forming in 2002, the program has connected its volunteers with more than 100,000 students across the country.

Hart, a psychiatrist, became involved in DBTS four years ago because she strongly believes in its mission: to increase the number of minority physicians and work toward eliminating racial and ethnic disparities in health care. Through DBTS, Hart and other physicians as well as minority medical students go into the community to introduce children to the medical profession and serve as potential role models. “It really helps for [the students] to see physicians who look like them,” she says.

Sometimes, Hart’s work involves addressing stereotypes—like the ones that have physicians making loads of cash and attending school forever. Hart tries to counteract these views by “telling them the kind of impact they can have on people’s lives.”

Hart says she and her DBTS associates are always trying to increase the “heads up factor.” That’s saying something that causes students to sit up and take notice. “When you speak from your heart about what you did and how you felt when you were their age, the students can connect



© Szabolcs Szekeres - Fotolia.com

because of the seriousness of this case, the MMA and the AMA sought to file the brief early.

This case calls into question the enforceability of medical staff by-laws—whether they are essentially a contract or are otherwise binding on the hospital—and how they may be changed in Minnesota.

In her denial of the amicus, the District Court judge stated that the court “appreciates and is mindful of the policy issues identified by the proposed *amici curiae* . . .

[however] there is no reason for the Court to believe that the parties to the litigation are unwilling or unable to identify and describe relevant policy issues, including those

identified by the proposed *amici curiae*.”

The case will now proceed on its merits, and the MMA will continue to explore other ways to support the profession as it moves forward.

EDITOR’S NOTE: *Keep track of legal events that affect your practice through MMA News Now, delivered to your email box free each Thursday. To subscribe, go to www.mnmed.org and look for “MMA News Now” under the “Publications” tab.*

We’re also on Facebook, Twitter, LinkedIn and YouTube.



to that,” Hart says. Students become inspired when they hear stories about overcoming adversity: “Knowing that I was a divorced mother of three toddlers without support, and I was able to go to medical school and do well is a testament that they can do it too, no matter what obstacles come their way.”

The interaction with the students doesn’t always end at school. Often, with their parents’ permission, Hart will correspond with students who are looking for more information on a medical career.

Working with students is just one way Hart gives back. She chairs both the MMA’s Minority and Cultural Affairs Committee and the AMA’s Minority Affairs Section. She also serves as vice president of the Zumbro Valley Medical Society and was the recipient of the 2010 Edward Drewry Henderson, M.D., Leadership Award. Plus, she is a member of the Minnesota Psychiatric Society Executive Council.

Originally from Chicago, Hart completed her residency at Mayo Clinic as part of the National Health Service Corps program. Because of her participation in that program, she was obligated to stay on for three years at the Federal Medical Center in Rochester, a Bureau of Prisons facility that provides specialized medical and mental health services to male offenders. She has stayed two years beyond her obligation. Now, Hart is the LGBT Special Emphasis Program Manager, ensuring that equal opportunity issues and concerns affecting LGBT employees at the center are adequately addressed.

Eliminating disparities is important to Hart, and it guides much of her work with the MMA’s Minority and Cultural Affairs Committee. Recently, the group began working on an initiative

to reduce the impact of hepatitis B in immigrant populations. As a result of its discussions, the committee is developing a card that patients who struggle with English can give to physicians to make sure they test for the potentially chronic condition.

The committee also plans to address HIV awareness among 20-somethings in the African-American and Hispanic communities. She notes that the group will work with churches in the African-American community as one way to connect directly with target audiences.

A third issue of concern for the committee is addressing the primary care workforce shortage by figuring out ways to help foreign-born physicians get involved in health care in the United States. “Some can be licensed as physicians or become medical assistants as a first step,” she says. The important thing is to get them involved in health care because they bring a perspective few other physicians have.

Despite her many commitments, Hart doesn’t appear to want to slow down with her volunteering. “After you get the bug you want to get more involved,” she says.

AT A **GLANCE**

MEDICAL SCHOOL

Rush Medical College of Rush University, Chicago

RESIDENCY

Mayo Graduate School of Medicine, 1995-2000

CURRENT PRACTICE

Psychiatrist at the Federal Medical Center in Rochester

INTERESTS/HOBBIES

Spending time with her adult children and granddaughter, attending the theater

VIEWPOINT

| by Dave Thorson, M.D.

Lessons for the future

By now you have probably read stories about the Attorney General's review of the debt collection and quality management practices used by Accretive Health on behalf of Fairview Health Services. In 2010, Fairview entered into a contractual relationship with the Chicago-based company for revenue cycle management and quality and total cost of care management. Minnesota Attorney General Lori Swanson has called into question the appropriateness of the relationship, citing, among other things, the fact that Accretive had access to in-

New payment models require us to pay greater attention to the cost of services we provide.

formation on patient health. The news about the Accretive-Fairview relationship prompted me to think about the challenges physicians face as we are held more accountable for the cost and quality of care we provide. I've identified three issues that I believe physicians should carefully consider; there are likely more.

Partnering with outside vendors

Monitoring the quality and cost of care delivery for a large group of patients requires sophisticated analytics. Such expertise is generally not among the core competencies for most physician practices. Vendors can offer practices the ability to complete such tasks as apply risk-assessment methods to better target

resources and interventions. Is your practice prepared to work with a vendor who can provide these services? And what role will health plans play in supporting this analysis function?

Aligning behavior and financial incentives

Changing or aligning financial incentives is an oft-repeated goal of state and federal health care reform proposals. The MMA has supported the idea of changing the way in which health care is paid for to better support quality care delivery, to allow more flexibility in how and where care is delivered, and to support better health outcomes.

Implicit in this goal is changing physician behavior. New payment models require us to pay greater attention to the cost of services we provide.

As physicians' practices assume greater accountability for cost and outcomes, they will have to become more adept at analyzing practice patterns, a responsibility that has largely been the domain of health plans and has led to initiatives such as prior authorization, retrospective reviews and performance profiling. Is your clinic prepared to monitor and manage the utilization patterns of its partners? How do you think physician utilization management programs should be structured to mitigate inappropriate financial conflicts of interest? How will physicians be assured that their management staff or their contracted vendors are using appropriate standards for valid and reliable performance measurement? How can physicians who serve complex and noncompliant patients feel comfortable continuing to care for those individuals?



Dave Thorson, M.D.
Chair, MMA Board of Trustees

Photo by Steve Weverka

Ensuring transparency

There is broad support for greater transparency in health care, including subjecting insurance rates, physician performance data, patient satisfaction scores and other information to greater public scrutiny. As physician practices assume new responsibilities, what information can and should be communicated to patients?

Should we have to reveal changes in compensation arrangements that include incentives for meeting utilization targets? Most of us would agree that patients should not have to worry that their physician is more concerned with saving money than with providing needed care; similarly, patients should not worry that their physician is willing to provide unnecessary care to generate money. But how can we assure our patients?

Many physicians, clinics and hospitals will need to work with vendors and other partners in order to report and use data, implement new reimbursement systems and develop relationships with other providers. The Accretive-Fairview experience may provide lessons for all of us as we navigate these uncharted waters.

VITAL SIGNS

MMA News in Review

Eurasian health care leaders visit MMA offices

It's a long way from Bishkek, Kyrgyzstan, to Minneapolis—at least physically. But in terms of health care issues, the two locales are not that far apart.

A group of 20 mid- to senior-level physicians and health care executives from nine Eurasian countries visited the MMA in



Members of a Eurasian delegation of physicians and health care executives ask questions of MMA staff.

early May as part of a month-long tour exploring the U.S. health care system.

“It’s interesting to hear that these physicians and health care administrators from the other side of the globe are dealing with many of the same issues we face in America—administrative burdens, quality of care, politics, train-

ing, etc.,” says Robert Meiches, M.D., MMA CEO.

The two-hour lunch meeting, which was also attended by Lyle Swenson, M.D., MMA president, and member Elena Polukhin, M.D., covered a variety of topics from credentialing to education to quality improvement.

The Eurasian delegation asked, among other things, if the MMA could endorse presidential candidates, whether the U.S. health care system provides incentives for preventive care and early diagnosis of disease, and for further explanation of the concept behind nonprofit health plans. This last question led to several follow-ups including an inquiry of what the health plans do with any profits they make.

The visit, organized by the U.S. Department of Commerce and International Trade Administration, was part of a SABIT (Special American Business Internship Training) Hospital Administration mission. The group also made stops in Washington, D.C., New York, Philadelphia and Tampa, Florida.

ACOs: One size doesn’t fit all

Although they are certainly a hot topic these days, accountable care organizations (ACOs) are not a one-size-fits-all proposition. Many physicians who belong to independent practices are trying to figure out how to work with them. Included in that group are MMA members Stuart Cox, M.D., head of an ear, nose and throat practice based in Woodbury, and Dave Thorson, M.D., board chair, and head of the Family Health Services clinic in St. Paul.

Earlier this year, Sen. Al Franken touched upon the subject of ACOs during a visit with the MMA’s trustees. Cox wanted to

hear more, so the MMA convened a meeting with the senator’s staff.

The creation of ACOs has been spurred by the 2010 Affordable Care of Act, which authorized the Medicare Shared Savings Program, and by the Pioneer ACO initiative developed by the Centers for Medicare and Medicaid Services (CMS). Several ACOs have formed in Minnesota through larger organizations such as Allina, Fairview and Park Nicollet; but many physicians who are not part of large systems, such as Cox and Thorson, are still figuring out how to best work with these new entities.

“The challenge for us is to come up with pared-down specific ideas that will improve the delivery and cost of health care and are politically feasible,” Cox says.

Dave Renner, the MMA’s director of state and federal legislation, says he thought the meeting was a good first step. “We appreciate the senator’s openness and interest in helping independent practitioners. While we support the new payment models designed to align incentives for quality patient care, ACOs are not the only way to achieve payment reform.”

Franken’s staff offered to follow up with CMS to ensure that independent clinics are part of future payment reform discussions.



Sen. Al Franken

Members making a difference

This spring, **Carl Patow, M.D.**, MMA member and executive director of HealthPartners Institute for Medical Education, received the Weinberg Award for academic medicine leadership from the Alliance of Independent Academic Medical Centers (AIAMC). Patow has served on the AIAMC board since 2006 and was its president from 2009 to 2012.

In late April, the Minnesota Academy of Family Physicians selected MMA member **Andrew Burgdorf, M.D.**, as its 2012 Family Physician of the Year. Other MMA members honored by the MAFP include **Macaran Baird, M.D.**, who received the President’s Award; **Laura Wellington, M.D.**, Resident of the Year; **Mark Yeazel, M.D.**, Researcher of the Year; **Ben Pederson**, Medical Student Award for Contributions to Family Medicine; and **Glenn Nemec, M.D.**, Merit Award for outstanding contributions to family medicine.

Also in April, MMA member **Maya Babu, M.D.**, was appointed to a one-year position as the Resident and Fellow Section member of the AMA Council on Legislation.

EDITOR’S NOTE: Keep track of news through MMA News Now, which is delivered to your email box free each Thursday. To subscribe, go to www.mnmed.org and look for “MMA News Now” under the “Publications” tab.

Current Trends in Hand Surgery

By Loree K. Kalliainen, M.D., M.A., FACS

■ Hand surgery became an established subspecialty between World Wars I and II. Prior to this time, hand injuries were cared for by various specialists—neurosurgeons, plastic surgeons, orthopedic surgeons, and general surgeons—each of whom would focus on their particular tissue within the hand. With the nearly 90,000 hand injuries sustained during World War II, military hospitals were created to deal solely with hand injuries, and hand specialists began to treat the hand as a single functional organ. This article briefly reviews the origin of the field and discusses current trends in hand surgery.

At the beginning of the 20th century, hand surgery was performed by a variety of surgeons—general surgeons, neurosurgeons, orthopedic surgeons and plastic surgeons. The injured hand could be operated on by multiple surgical teams, each focused on its particular area of interest or expertise,¹⁻³ and often, the care of the hand was left to the junior members of a group. It gradually became recognized that caring for the hand as a functional entity was more important than caring for each of the hand's individual parts. Thus, during the period between the two World Wars, hand surgery became a discrete specialty.⁴ The publication of two text books contributed much to the development of hand surgery as a recognizable specialty: Kanavel's text *Infections of the Hand*, published in 1912, and Bunnell's *Surgery of the Hand*, first published in 1944.¹⁵ During World War II, more

than 89,000 hand injuries occurred, leading the government to the establish military hand surgery centers.^{2,6} Those centers were staffed by both military and civilian surgeons who had a special interest and expertise in treating hand injuries. In 1946, 35 hand specialists created the American Society for Surgery of the Hand (ASSH).⁶ The initial membership included general surgeons (14), plastic surgeons (13) and orthopedic surgeons (eight). As the field grew, the society became more inclusive; today the ASSH has approximately 1,300 members worldwide. As the specialty matured and as its knowledge base grew, academic hand surgeons discussed subspecialty certification.⁶ It was decided that, rather than create a discrete boarded specialty as Sweden did, a surgeon in the United States wishing to specialize in hand surgery could do preliminary training in general, plastic or

orthopedic surgery followed by a hand fellowship.^{6,7}

This article highlights recent trends in hand surgery, focusing on techniques and procedures involving the entire hand as well as those that involve a particular tissue. Some of the procedures are relatively widely accepted, others are accepted but may not be performed often because of the rarity of the condition they correct, and still others are in transition as research attempts to determine their comparative effectiveness and optimal indications.

Two Developments

■ Surgery Without Sedation

For decades, medical students have recited a memorable rhyme: "No epinephrine in fingers, nose, gonads or toes." This cautionary statement began with the hypothesis that epinephrine added to local anesthetic could cause vasoconstriction and lead to tissue ne-

crisis in terminal locations. Recent work has shown that early local anesthetic agents were chemically unstable and could be toxic to tissues, and that tissue damage was more likely to be related to the anesthetic agent than the epinephrine added to it. A large set of well-designed investigations demonstrated the safety and efficacy of local anesthesia containing epinephrine.^{8,9} Epinephrine prolongs the duration of the local anesthetic and decreases local bleeding. This allows hand surgery to be done without a tourniquet, and it is one reason why “wide-awake hand surgery” or surgery without sedation has gained popularity.⁹

Surgery without sedation has been promoted by Canadian plastic and hand surgeon Donald LaLonde, M.D.,¹⁰ who showed that procedures as varied as carpal tunnel release and certain tendon transfers can be done in patients of all ages under local anesthesia in an office setting rather than in the operating room.

■ Hand Transplantation

At the other end of the spectrum in terms of complexity is hand transplantation. The first successful hand transplant was performed in France in 1998.¹¹ However, because of episodes of rejection, the transplanted hand eventually was removed at the patient’s request. At the time, members of the hand surgery community criticized the surgeons who performed the procedure, arguing that the patient was not a good candidate and that the case was done hastily. The following year, the first transplant with extended success was performed at the Kleinert Hand Institute.¹² Ensuing articles focused on ethics and opinions regarding the value of, indications for and, finally, technical aspects of the procedure.¹³⁻¹⁶ Despite early opposition, institutions throughout the world are now exploring the logistics of becoming hand transplantation centers, and there is now an international registry of hand transplants to monitor outcomes.¹⁷

..... Skin and Adipose Tissue Procedures

■ Dermal Regeneration Templates

In conditions where the skin has been completely lost, skin grafts or local, regional or distant tissue flaps may be needed to cover deep structures such as tendon, nerve or bone. Problems associated with skin grafts include fragility, stiffness and loss of surface area with healing; in addition, flaps create a secondary wound and may be bulky or cosmetically undesirable. The use of dermal regeneration templates, collagen scaffolds that support wound healing and are made of materials that are natural (animal, human or plant sources) or synthetic or a blend of both, has become more widespread. These templates add durability, limit wound contracture and prevent the need for more invasive surgical procedures.¹⁸ A dermal template is placed in the wound bed and, once it has been vascularized, a skin graft is placed over it. This does

prolong treatment, but the ultimate outcome may be better than with a skin graft alone. Both skin grafting and placement of dermal templates are less invasive than flap surgery. Dermal templates are now used in patients with burns, in reconstruction of congenital hand deformities and following trauma.¹⁸⁻²¹

■ Collagenase and Fat Grafting for Dupuytren’s Disorder

Dupuytren’s disorder is a contracture of palmar fascia causing flexion deformities of the digits. Initially, it was believed to primarily affect males of northern European heritage; it has since been recognized in men and women of all ethnic backgrounds.²²⁻²⁴ Treatment options have included stretching, dividing the palmar cords with needles, surgical excision and, most recently, dissolution with collagenase.²⁵⁻²⁷ For trained surgeons and selected patients, the use of collagenase

Off-Label Use of Onabotulinum Toxin A for Hand Conditions

Onabotulinum toxin A has been used since the late 1980s for the treatment of blepharospasm, strabismus and glabellar lines. It decreases the ability of a muscle fiber to contract by inhibiting the release of acetylcholine from nerves. It is currently FDA-approved for those disorders as well as for treating chronic migraines, axillary hyperhidrosis, cervical dystonia and upper-limb spasticity.¹ Early evidence supports the use of botulinum toxin in an off-label fashion to treat palmar hyperhidrosis, focal hand dystonia, and Raynaud’s and other vasospastic disorders.²⁻⁷ It is also successful, for reasons yet unclear, in relieving vascular spasticity and controlling pain. Proposed mechanisms of action include inhibiting the release of inflammatory neuropeptides and decreasing the expression of pain receptors in the dorsal root ganglia.^{8,9}

REFERENCES

1. Medication Guide Botox. Available at: www.fda.gov/downloads/Drugs/DrugSafety/UCM176360.pdf. Accessed May 10, 2012.
2. Ito K, Yanagishita T, Ohshima Y, Tamada Y, Watanabe D. Therapeutic effectiveness of botulinum toxin type A based on severity of palmar hyperhidrosis. *J Dermatol*. 2011;38(9):859-63.
3. Lungu C, Karp BI, Alter K, Zolbrod R, Hallett M. Long-term follow-up of botulinum toxin therapy for focal hand dystonia: outcome at 10 years or more. *Mov Disord*. 2011;26(4):750-3.
4. Neumeister MW. Botulinum toxin type A in the treatment of Raynaud’s phenomenon. *J Hand Surg Am*. 2010;35(12):2085-92.
5. Neumeister MW, Chambers CB, Herron MS, et al. Botox therapy for ischemic digits. *Plast Reconstr Surg*. 2009;124(1):191-201.
6. Fregene A, Ditmars D, Siddiqui A. Botulinum toxin type A: a treatment option for digital ischemia in patients with Raynaud’s phenomenon. *J Hand Surg Am*. 2009;34(3):446-52.
7. Van Beek AL, Lim PK, Gear AJ, Pritzker MR. Management of vasospastic disorders with botulinum toxin A. *Plast Reconstr Surg*. 2007;119(1):217-26.
8. Aoki KR, Francis J. Updates on the antinociceptive mechanism hypothesis of botulinum toxin A. *Parkinsonism Relat Disord*. 2011;17 Suppl 1:S28-33.
9. Xiao L, Cheng J, Dai J, Zhang D. Botulinum toxin decreases hyperalgesia and inhibits P2X(3) receptor over-expression in sensory neurons induced by ventral root transection in rats. *Pain Med*. 2011;12(9):1385-94.

is relatively straightforward. The collagenase is injected into the cord, and the next day the patient returns to the clinic where the cord is cracked and the finger is forced into extension. Complications have included local tissue redness that mimics infection, tearing of the skin and rupture of tendons (if the collagenase is injected too deeply).^{26,28}

In cases of recurrent and highly aggressive Dupuytren's disease of the palm, fat grafting has been proposed as a surgical adjunct to needle aponeurotomy. It is recognized that adult human adipose tissue contains pluripotent adipose-derived stem cells. These cells can be harvested from patients using liposuction and are capable of differentiating into multiple tissue types. In fat grafting, it has been proposed that pluripotent cells repair the overlying tissue.^{29,30} More commonly, fat grafting has been used for improving the contour of the dorsal hand and masking prominent dorsal veins.³¹ Fat grafting complications include resistant infections and contour irregularities, and often there is a need for additional procedures. Refinements in the fat-harvesting technique have reduced the need for multiple procedures.^{31,32}

.....
Tendon Procedures

■ **Extensor Tendon Yoke Splinting**

The most common complication of extensor tendon repair has been loss of flexion.³³ Dynamic extension splinting has improved the ultimate outcome of extensor tendon repair; but the technique is device-dependent and wearing the device can be unwieldy.^{34,35} The most recent development has been allowing extensor tendon motion immediately after surgery.^{35,36} By placing the injured finger in a slightly extended position, the tendon is under less stress, and the patient can immediately move the finger without risk of rupture. This method is easy to implement, results in better compliance on the part of patients than having to wear a bulky splint and ultimately achieves a near-normal range of motion.^{35,36}

.....
Bone and Joint Procedures

■ **Hemi-hamate Joint Reconstruction**

The proximal interphalangeal joint is responsible for much of the dexterity of the finger, and injuries can have long-term sequelae. Options for repair may be limited, and problems with scarring and stiffness are common.³⁷ Joint implants are sometimes possible, depending on the digit involved and the needs of the patient. Joint fusion provides stability at the expense of motion. Volar plate advancements may stabilize the joint but also lead to stiffness. Transferring vascularized joints from the toes has been offered as an option, but this is rarely done.³⁸ A procedure that has demonstrated slightly more predictable outcomes is the use of the hemi-hamate bone graft to reconstruct a partial joint loss at the base of the middle phalanx. One of the articular surfaces of the hamate bears a striking resemblance to the shape of the volar base of the middle phalanx, and unstable fracture dislocations can be treated by transferring this section of bone from the dorsal wrist to the volar aspect of the finger.³⁹ Repairing like with like is a goal, and this bone graft has shown promising results with range of motion being approximately 70 degrees to 85 degrees and grip strength between 80% to 95% of the contralateral, uninjured side.³⁹⁻⁴¹

■ **Low-Intensity Pulsed Ultrasound**

The scaphoid bone in the wrist, historically called the navicular, is the one most frequently broken by a fall onto the outstretched hand. Unfortunately, the blood supply to the scaphoid is tenuous, and a fracture can be slow to heal.^{42,43} Even if the scaphoid is in appropriate alignment or if it has been stabilized with a pin or screw, there is still a chance that a fracture may not heal, leading to scaphoid necrosis and arthritic destruction of the wrist. Nonunion rates approach 40%.^{43,44} Risk factors for nonunion or delayed union are a proximal pole fracture, delayed diagnosis of the fracture and tobacco use. To promote revascularization of the scaphoid, pulsed ultrasound has been used if

there is no evidence of healing within the first two months following fracture.⁴⁵⁻⁴⁸ In studies using low-intensity pulsed ultrasound, union rates ranged from 86% to 100% within nine to 22 weeks.

■ **Volar Plating**

Distal radius fractures are commonly managed by hand surgeons as they are often associated with bone and ligament injuries to the carpus. The incidence of concomitant injury ranges from 7% to 100% depending on the intensity of the evaluation.⁴⁹⁻⁵¹ During the past 10 to 12 years, volar locking plates have come into vogue for treating distal radius fractures, but their widespread use is now being questioned. Their use may be associated with greater rates of complications compared with other treatment choices. Other accepted means of treatment include cast management, percutaneous pinning, dorsal plating and use of external fixation devices. Current evidence does not indicate superiority of any single treatment,⁵²⁻⁵⁶ and investigators are trying to determine the best indication for each technique.

.....
Nerve Repair

■ **Nerve Transfer**

When a nerve is irreparable or if functional recovery of muscles in the hand cannot be expected with repair, nerve transfers can be offered as an option for recovery of distal function.⁵⁷ In much the same way that tendon transfers use a functional tendon to replace the one that is no longer available, a nerve transfer brings viable axons closer to a denervated muscle to allow for reinnervation during an acceptably short time span. Nerves grow at a maximum of one inch per month, and if a denervated muscle is not reinnervated within 18 months it will never be able to be reinnervated and its function will be lost. In the case of a lacerated ulnar nerve, an adjacent expendable motor nerve, the anterior interosseous branch of the median nerve, can be cut distally and sewn to the distal branch of the ulnar motor nerve so that its branches reinnervate the muscles of the

hand that are innervated with the ulnar nerve.⁵⁸ Because this nerve lies within a few inches of the ulnar-innervated muscles, the patient has a better chance of functional recovery. The brain can be retrained to move the muscles of the hand in at least a rudimentary fashion. Nerve transfers also can compensate for injuries to the motor nerve and sensory injuries to the median and radial nerves.^{59,60}

■ **Nerve Conduit**

When the ends of a transected nerve cannot be directly coapted because of retraction, scarring or loss of a segment of nerve, the nerve gap is generally grafted with an expendable nerve from elsewhere in the body. If the gap is short, if the patient or surgeon wishes to avoid a secondary surgical site or if the need for graft material is greater than the supply, bioabsorbable conduits through which native nerve can grow can be created.⁶¹⁻⁶³ The way this works is that the divided ends of a nerve are plugged into the conduit to allow nerve fibers to grow across the gap in a more controlled fashion. The use of nerve conduits has been studied extensively in animal models and in humans with nerve injuries; it has been found that the cut nerve will probably not consistently travel more than 2.5 cm across a conduit in an adult, although one recent meta-analysis found that the distance may be greater for the median nerve.^{61,64} The nerve conduit probably is less effective when used in a larger mixed-motor and sensory nerve more proximal in the arm in adults. Future research will focus on materials and structural design to promote nerve ingrowth across greater distances.

.....
Conclusion

Hand surgery is fascinating because of the complexity of the anatomy, the variety of problems that can be addressed and the potential for functional recovery. Since it became a specialty more than 60 years ago, the field has continued to attract surgeons with a temperament and philosophical bent to care for the hand as a unified organ rather than a collec-

tion of parts. Given the importance of hand function to daily life, the frequency of injuries and the increasing number of disorders associated with an aging population, a considerable amount of research has been taking place, some of which has generated controversy. Our knowledge and understanding of best practices will continue to evolve as researchers develop new ways to treat conditions and injuries affecting the hand. **MM**

Loree Kalliainen is a surgeon in the department of plastic and hand surgery at Regions Hospital in St. Paul. She also is program director of the Regions/HealthPartners IME hand surgery fellowship and a clinical assistant professor at the University of Minnesota.

.....
REFERENCES

1. Atkins H in *The General and Plastic Surgery of the Hand*. Clarkson P and Pelly A, eds. Oxford; Blackwell Scientific Publications, 1962.
2. Omer GE Jr. Development of hand surgery: education of hand surgeons. *J Hand Surg Am*. 2000;25(4):616-28.
3. Nagle DJ. The Chicago School of Hand Surgery. *J Hand Surg Am*. 2003;28(5):724-8.
4. Gordon-Taylor G. in *Surgery of Repair as Applied to Hand Injuries*. Rank BK and Wakefield AR, eds. London; E&S Livingstone Ltd, 1953.
5. Bolton H. Founders of hand surgery. The Chicago school of hand surgeons. *J Hand Surg Br*. 1991;16(1):116-7.
6. Smith RJ. Subcertification for hand surgery. *J Hand Surg Am*. 1982;7(2):107-12.
7. Hagert CG. The history of hand surgery in Sweden. *J Hand Surg Br*. 2001 Feb;26(1):78-83.
8. Thomson CJ, Lalonde DH, Denkler KA, Feicht AJ. A critical look at the evidence for and against elective epinephrine use in the finger. *Plast Reconstr Surg*. 2007;119(1):260-6.
9. Lalonde D, Bell M, Benoit P, Sparkes G, Denkler K, Chang P. A multicenter prospective study of 3,110 consecutive cases of elective epinephrine use in the fingers and hand: the Dalhousie Project clinical phase. *J Hand Surg Am*. 2005;30(5):1061-7.
10. Lalonde DH. Reconstruction of the hand with wide-awake surgery. *Clin Plast Surg*. 2011; 38(4):761-9.
11. Dubernard JM, Owen E, Herzberg G, et al. Human hand allograft: report on first 6 months. *Lancet*. 1999;353(9161):1315-20.
12. Jones JW, Gruber SA, Barker JH, Breidenbach WC. Successful hand transplantation. One-year follow-up. Louisville Hand Transplant Team. *N Engl J Med*. 2000;343(7):468-73.
13. Edgell SE, McCabe SJ, Breidenbach WC, Neace WP, Lajoie AS, Abell TD. Different reference frames can lead to different hand transplantation decisions by patients and physicians. *J Hand Surg Am*. 2001;26(2):196-200.
14. Breidenbach WC 3rd, Tobin GR 2nd, Gorantla VS, Gonzalez RN, Granger DK. A position statement in support of hand transplantation. *J Hand Surg Am*. 2002;27(5):760-70.
15. Jones NF. Concerns about human hand transplantation in the 21st century. *J Hand Surg Am*. 2002;27(5):771-87.
16. Ravindra KV, Wu S, Bozucik L, Xu H, Breidenbach WC, Ildstad ST. Composite tissue transplantation: a rapidly advancing field. *Transplant Proc*. 2008;40(5):1237-48.

17. Petruzzo P, Lanzetta M, Dubernard JM, et al. The International Registry on Hand and Composite Tissue Transplantation. *Transplantation*. 2010;90(12):1590-4.
18. Askari M, Cohen MJ, Grossman PH, Kulber DA. The use of acellular dermal matrix in release of burn contracture scars in the hand. *Plast Reconstr Surg*. 2011;127(4):1593-9.
19. Cuadra A, Correa G, Roa R, et al. Functional results of burned hands treated with Integra. *J Plast Reconstr Aesthet Surg*. 2012;65(2):228-34.
20. Jung JJ, Woo AS, Borschel GH. The use of Integra bilaminar dermal regeneration template in apert syndactyly reconstruction: a novel alternative to simplify care and improve outcomes. *J Plast Reconstr Aesthet Surg*. 2012;65(1):118-21.
21. Weigert R, Choughri H, Casoli V. Management of severe hand wounds with Integra dermal regeneration template. *J Hand Surg Eur*. 2011;36(3):185-93.
22. Shih B, Bayat A. Scientific understanding and clinical management of Dupuytren disease. *Nat Rev Rheumatol*. 2010;6(12):715-26.
23. Gudmundsson KG, Arngrimsson R, Sigfusson N, Bjornsson A, Jonsson T. Epidemiology of Dupuytren's disease: clinical, serological, and social assessment. The Reykjavik Study. *J Clin Epidemiol*. 2000; 53(3):291-6.
24. Muguti GI, Appelt B. Dupuytren's contracture in black Zimbabweans. *Cent Afr J Med*. 1993;39(6): 129-32.
25. Desai SS, Hentz VR. The treatment of Dupuytren disease. *J Hand Surg Am*. 2011;36(5):936-42.
26. Gilpin D, Coleman S, Hall S, Houston A, Karrasch J, Jones N. Injectable collagenase Clostridium histolyticum: a new nonsurgical treatment for Dupuytren's disease. *J Hand Surg Am*. 2010;35(12):2027-38.
27. Chen NC, Shauver MJ, Chung KC. Cost-effectiveness of open partial fasciectomy, needle aponeurotomy, and collagenase injection for dupuytren contracture. *J Hand Surg Am*. 2011;36(11):1826-34.
28. Zhang AY, Curtin CM, Hentz VR. Flexor tendon rupture after collagenase injection for Dupuytren contracture: case report. *J Hand Surg Am*. 2011;36(8):1323-5.
29. Hovius SE, Kan HJ, Smit X, Selles RW, Cardoso E, Khouri RK. Extensive percutaneous aponeurotomy and lipografting: a new treatment for Dupuytren disease. *Plast Reconstr Surg*. 2011;128(1):221-8.
30. Sun N, Panetta NJ, Gupta DM, Wilson KD, Lee A, Jia F, Hu S, Cherry AM, Robbins RC, Longaker MT, Wu JC. Feeder-free derivation of induced pluripotent stem cells from adult human adipose stem cells. *Proceedings of the National Academy of Sciences of the United States of America*. 2009;106(37):15720-5.
31. Coleman SR. Hand rejuvenation with structural fat grafting. *Plast Reconstr Surg*. 2002;110(7):1731-44; discussion 1745-7.
32. Galea LA, Nicklin S. Mycobacterium abscessus infection complicating hand rejuvenation with structural fat grafting. *J Plast Reconstr Aesthet Surg*. 2009;62(2):15-6.
33. Newport ML, Blair WF, Steyers CM Jr. Long-term results of extensor tendon repair. *J Hand Surg Am*. 1990;15(6):961-6.
34. Neuhus V, Wong G, Russo KE, Mudgal CS. Dynamic splinting with early motion following zone IV/V and TI to TIII extensor tendon repairs. *J Hand Surg*. 2012;37(5):933-7.
35. Khandwala AR, Webb J, Harris SB, Foster AJ, Elliot D. A comparison of dynamic extension splinting and controlled active mobilization of complete divisions of extensor tendons in zones 5 and 6. *J Hand Surg Br*. 2000;25(2):140-6.
36. Howell JW, Merritt WH, Robinson SJ. Immediate controlled active motion following zone 4-7 extensor tendon repair. *J Hand Ther*. 2005;18(2):182-90.
37. Chiu DT, Lee J. Autogenic heterotopic vascularized proximal interphalangeal joint transplantation in children. *Microsurgery*. 2011;31(3):198-204.
38. Freiberg A, Pollard BA, Macdonald RW, Duncan MJ. Management of proximal interphalangeal joint injuries. *Hand Clin*. 2006;22(3):235-42.

39. Williams RM, Kiefhaber TR, Sommerkamp TG, Stern PJ. Treatment of unstable dorsal proximal interphalangeal fracture/dislocations using a hemi-hamate autograft. *J Hand Surg Am.* 2003;28(5):856-65.
40. Afendras G, Abramo A, Mrkonjic A, Geijer M, Kopylov P, Tagil M. Hemi-hamate osteochondral transplantation in proximal interphalangeal dorsal fracture dislocations: a minimum 4 year follow-up in eight patients. *J Hand Surg Eur Vol.* 2010;35(8):627-31.
41. Calfee RP, Kiefhaber TR, Sommerkamp TG, Stern PJ. Hemi-hamate arthroplasty provides functional reconstruction of acute and chronic proximal interphalangeal fracture-dislocations. *J Hand Surg Am.* 2009;34(7):1232-41.
42. Ibrahim T, Qureshi A, Sutton AJ, Dias JJ. Surgical versus nonsurgical treatment of acute minimally displaced and undisplaced scaphoid waist fractures: pairwise and network meta-analyses of randomized controlled trials. *J Hand Surg Am.* 2011;36(11):1759-1768.
43. Wong K, von Schroeder HP. Delays and poor management of scaphoid fractures: factors contributing to nonunion. *J Hand Surg Am.* 2011;36(9):1471-4.
44. Dinah AF, Vickers RH. Smoking increases failure rate of operation for established non-union of the scaphoid bone. *Int Orthop.* 2007;31(4):503-5.
45. Pounder NM, Harrison AJ. Low intensity pulsed ultrasound for fracture healing: a review of the clinical evidence and the associated biological mechanism of action. *Ultrasonics.* 2008;48(4):330-8.
46. Ricardo M. The effect of ultrasound on the healing of muscle-pediculated bone graft in scaphoid non-union. *Int Orthop.* 2006;30(2):123-7.
47. Divelbiss BJ, Adams BD. Electrical and ultrasound stimulation for scaphoid fractures. *Hand Clin.* 2001;17(4):697-701.
48. Nolte PA, van der Krans A, Patka P, Janssen IM, Ryaby JP, Albers GH. Low-intensity pulsed ultrasound in the treatment of nonunions. *J Trauma.* 2001;51(4):693-702; discussion 702-3.
49. Komura S, Yokoi T, Nonomura H, Tanahashi H, Satake T, Watanabe N. Incidence and characteristics of carpal fractures occurring concurrently with distal radius fractures. *J Hand Surg Am.* 2012;37(3):469-76.
50. Kordasiewicz B, Pomianowski S, Orlowski J, Rapala K. Interosseous ligaments and TFCC lesions in intraarticular distal radius fractures—radiographic versus arthroscopic evaluation. *Ortop Traumatol Rehabil.* 2006;8(3):263-7.
51. Frank J, Pralle H, Lehnert M, Marzi I. [Concomitant injuries of distal radius fractures]. *Unfallchirurg.* 2010;113(10):796, 797-803.
52. Yu YR, Makhni MC, Tabrizi S, Rozental TD, Mundanathanam G, Day CS. Complications of low-profile dorsal versus volar locking plates in the distal radius: a comparative study. *J Hand Surg Am.* 2011;36(7):1135-41.
53. Lee YS, Wei TY, Cheng YC, Hsu TL, Huang CR. A comparative study of Colles' fractures in patients between fifty and seventy years of age: percutaneous K-wiring versus volar locking plating. *Int Orthop.* 2012;36(4):789-94.
54. Grewal R, MacDermid JC, King GJ, Faber KJ. Open reduction internal fixation versus percutaneous pinning with external fixation of distal radius fractures: a prospective, randomized clinical trial. *J Hand Surg Am.* 2011;36(12):1899-906.
55. Wilcke MK, Abbaszadegan H, Adolphson PY. Wrist function recovers more rapidly after volar locked plating than after external fixation but the outcomes are similar after 1 year. *Acta Orthop.* 2011; 82(1):76-81.
56. Gereeli A, Nalbantoglu U, Kocaoglu B, Turkmen M. Comparison of palmar locking plate and K-wire augmented external fixation for intra-articular and comminuted distal radius fractures. *Acta Orthop Traumatol Turc.* 2010;44(3):212-9.
57. Boyd KU, Nimigan AS, Mackinnon SE. Nerve reconstruction in the hand and upper extremity. *Clin Plast Surg.* 2011;38(4):643-60.
58. Brown JM, Yee A, Mackinnon SE. Distal median to ulnar nerve transfers to restore ulnar motor and sensory function within the hand: technical nuances. *Neurosurgery.* 2009;65(5):966-77; discussion 977-8.
59. Bertelli JA, Ghizoni MF. Very distal sensory nerve transfers in high median nerve lesions. *J Hand Surg [Am].* 2011;36(3):387-93.
60. Brown JM, Tung TH, Mackinnon SE. Median to radial nerve transfer to restore wrist and finger extension: technical nuances. *Neurosurgery.* 2010;66(3 Suppl Operative):75-83; discussion 83.
61. Jiang X, Lim SH, Mao HQ, Chew SY. Current applications and future perspectives of artificial nerve conduits. *Exp Neurol.* 2010;223(1):86-101.
62. de Ruiter GC, Malessy MJ, Yaszemski MJ, Windebank AJ, Spinner RJ. Designing ideal conduits for peripheral nerve repair. *Neurosurg. focus.* 2009;26(2):E5.
63. Meek MF, Coert JH. US Food and Drug Administration /Conformit Europe- approved absorbable nerve conduits for clinical repair of peripheral and cranial nerves. *Ann Plast Surg.* 2008;60(4):466-72.
64. Yang M, Rawson JL, Zhang EW, Arnold PB, Lineaweaver W, Zhang F. Comparisons of outcomes from repair of median nerve and ulnar nerve defect with nerve graft and tubulization: a meta-analysis. *J Reconstr Microsurg.* 2011;27(8):451-60.

Call for papers

Minnesota Medicine invites contributions (essays, poetry, commentaries, clinical updates, literature reviews and original research) on these topics:

Infectious Disease
Articles due June 20

Common Ground
(What unites physicians in an age of specialization?)
Articles due July 20

Genetics
Articles due August 20

Health Care Delivery
Articles due September 20

Food and Nutrition
Articles due October 20

We are also welcome articles on other topics.

Manuscripts and a cover letter can be sent to cpeota@mnmed.org.

For more information, go to www.minnesotamedicine.com or call Carmen Peota at 612-362-3724.

The Evolution of Wrinkle Removal

Use of Lasers and Other Devices in Facial Rejuvenation

By Richard H. Tholen, M.D., FACS

■ Lasers have revolutionized facial rejuvenation. Various wavelengths, more powerful machines allowing shorter shutter times and more precise vaporization, and other innovations led physicians and their patients to embrace ablative laser technology. The results have not always been positive, however. Over-adoption by poorly trained physicians led to highly publicized problems and the development of a whole class of nonablative machines as well as fractional laser technology. This article reviews the evolution of wrinkle removal by lasers and other devices.

For decades, CO₂ lasers have been used to create smoother skin. These lasers have been used for superficial skin removal or resurfacing since shortly after their development in 1964. CO₂ lasers operate at a wavelength of 10,600 nm in the far infrared, where the energy is absorbed by water in the skin. The first CO₂ lasers were relatively low-powered (<100 watts), requiring longer on-times and causing deeper thermal damage to the skin. For that reason, the early low-power CO₂ lasers were used more for vaporizing warts or lesions than for making skin look younger. For those who did undergo laser dermabrasion or “laserabrasion” (removal of the upper layers of the skin), healing time was lengthy (usually weeks), and scarring (color-lightened and/or shiny skin) occurred all too frequently. As a result, low-power CO₂ laserabrasion was never widely adopted. However, advances in laser instrumentation in the early 1990s sparked renewed interest in the use of lasers for removing wrinkles and rejuvenating skin. This article reviews the evolution of lasers since then and the development of other devices for skin rejuvenation.

First-Generation Resurfacing Lasers (CO₂)

In the early 1990s, short-pulsed, high-energy CO₂ laser technology (Ultrapulse) was introduced by Coherent Medical Group (now Lumenis).¹ This allowed for a much higher power

(500 watts peak output) CO₂ laser to be used in extremely short pulses (<1 msec) to vaporize a precise thickness of skin (100 microns, or 0.1mm), the result being char-free tissue removal and little heat damage to deeper structures. Coherent also introduced a computer pattern generator (CPG) that allows rapid coverage of larger areas with precisely spaced 2.25 mm spots in patterns that vary in size, shape and density. With the CPG, entire facial resurfacing can be done in an hour by an experienced surgeon. Using the 3 mm handpiece without the CPG takes two to three times as long. This laser is still in clinical use, although the problem of delayed skin hypopigmentation has caused most operators to either abandon their Coherent Ultrapulse or use it at very low intensities, which limits the degree of improvement. More recent developments by Lumenis include a fractional microscanner (DeepFX) that can be used instead of the CPG (now called ActiveFX UltraScan) or in combination with it (TotalFX).

These first-generation CO₂ resurfacing lasers were a paradigm shift. They were a dramatic change from previous wrinkle-removal procedures (predominantly dermabrasion and chemical peeling). Patients, doctors and the media deemed them “the next new thing.”

The way they work is that each pulse removes 100 microns (±40 microns) of tissue; thus, one to four passes of the laser in

each anatomic area are necessary to remove enough skin layers to effectively diminish wrinkles or scars. Since each pulse generates enough energy for tissue vaporization in less than 1 msec, collateral (forward) thermal damage and scar risk is limited, yet the energy is just enough to cause collagen fibers to contract and shorten, which is the first part of wrinkle removal.

A new epithelial surface then grows from the undamaged epithelial cells lining the adnexal structures of the skin (hair follicles and sweat gland pores) during the next seven to 10 days. The healing phase causes new collagen and new elastic fibers to form in the upper dermis, further tightening the skin over four to six months. Facial skin rich in adnexal structures re-epithelializes easily, while skin from the neck or other areas with fewer adnexal elements has poorer healing capability and a higher risk for scarring.

Despite promising results in many patients, first-generation CO₂ laser outcomes were not without downsides.² Although the majority of results following CO₂ laser resurfacing were without a doubt remarkable and long-lasting, time and experience have exposed several concerns.³ One is prolonged redness during the healing phase. Although most female patients were able to wear normal make up after several weeks and most male patients were able to pass off the residual redness as sunburn, some found redness could last as long as six months.

An even more significant concern was that longer-term follow-up (one to two years) has shown that some CO₂ resurfacing patients develop hypopigmentation (lightening of skin color) after aggressive wrinkle removal.⁴ This can leave a visible and unsightly line of demarcation at the jawline or between the treated (lighter) and untreated (darker) areas, particularly in patients with vascular or pigmented areas of neck skin (poikiloderma of Civatte).

Unfortunately, any physician, regardless of specialty or training and experience, could buy or lease one of these \$100,000-plus machines and start offering treatments. Eager manufacturers induced physicians to purchase or lease this equipment, usually on five-year terms, after only a weekend laser course. “New” laser technology and different wavelengths are typically introduced before the end of the five-year lease or purchase agreement period. This has led to physicians who do limited amounts of laser surgery being stuck with old technology, in addition to lacking proficiency.

.....
Second-Generation Resurfacing Lasers (Erbium:YAG)

Partly because of concerns about complications, the second-generation entry in the skin resurfacing arena—the short-pulse Erbium:YAG laser—was developed.⁵ It promised more rapid healing and less redness than earlier CO₂ lasers.

The Erbium:YAG laser operates in the near-infrared wavelength (2,940 nm). Energy at this wavelength is strongly absorbed by water, in fact, nearly 20 times more strongly than

CO₂ laser energy at 10,600 nm (far infrared). This makes the Erbium:YAG laser capable of extremely thin-layer tissue removal with scant thermal damage that stimulates less collagen shortening.

The Erbium:YAG laser became a more attractive alternative for patients with less severe aging, sun damage and/or wrinkling. Patients who had Erbium:YAG resurfacing experienced faster healing (about a week) and less erythema than those who were treated with first-generation CO₂ lasers. However, less tissue removal meant results that were very superficial. Unless many more passes are carried out, this laser cannot successfully remove deeper wrinkles. The manufacturers’ promise of “equal effectiveness, but less redness and more rapid healing” has essentially proven to be more hype than fact, not because of any inherent fault in this laser but rather because it took so many passes in order to be effective. Most physicians who had experience with the Coherent Ultrapulse laser were used to doing no more than one to four passes in any given skin area, so there was a natural reluctance to use the Erbium:YAG laser and do the number of passes needed to achieve good results.⁶

Many Erbium:YAG lasers remain on the market; and many providers who use them still do not perform enough passes in the treated areas, producing disappointing results in some cases. Although scarring or other problems are quite rare, even in relatively inexperienced hands, a few widely publicized cases of “disaster by laser” began to scare patients as well as their doctors. These stories were more common with first-generation CO₂ lasers than with second-generation Erbium:YAG lasers; but buyers’ remorse and new purchase anxiety began to turn the “jump on the bandwagon” mentality into an “abandon ship” attitude.

.....
Third-Generation–Combination (Erbium:YAG/CO₂) Laser

Third-generation technology combines the CO₂ and Erbium:YAG laser wavelengths (both beams in the same spot). The Erbium:YAG wavelength first vaporizes a very thin layer of skin tissue, allowing a concomittant low-power CO₂ laser pulse (0 to 10 watts) to effectively shrink the dermal collagen with much less thermal damage and redness (inflammation). This prevents the hypopigmentation and visible lines of demarcation seen with the higher-power first-generation CO₂ lasers and gives the results that each of the first two generations of devices sought but could not quite achieve separately. The Derma-K laser by ESC Medical Systems was the first combination (dual-wavelength) laser in the marketplace;⁷ other manufacturers developed long-pulse Erbium:YAG lasers⁸ to simulate the combined wavelength effect. Some physicians use a two-laser approach to facial skin resurfacing, which requires availability of both a first-generation CO₂ laser and a second-generation Erbium:YAG laser in the same operating room, not to mention careful attention to which areas have been treated first by

Erbium:YAG laser energy and then by lower-power CO₂ laser energy. Because this is neither practical nor easy, it is rarely done.

Our experience with the third-generation laser since 1998 has shown very good overall results in patients with varying severity of wrinkles, acne scarring or sun-damaged skin. Healing takes about one week and patients experience mild redness. Afterward, patients report having fresher, less wrinkled skin. This third-generation laser has not caused the hypopigmentation or visible lines of demarcation that troubled many patients treated with the older CO₂ resurfacing lasers.⁹

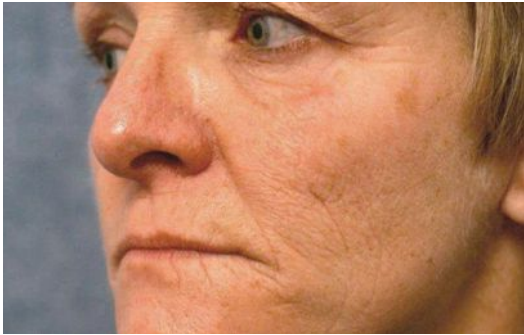By the time the third-generation resurfacing lasers were being marketed to physicians in 1998 and 1999, however, the bloom was off the rose and laser resurfacing was no longer a procedure every physician who did cosmetic surgery wanted to do. Many physicians knew of a friend or colleague who invested in either the first- or second-generation lasers and now no longer used them because of problems or lawsuits from dissatisfied patients. In addition, the public's fascination had waned, and the number of procedures performed nationally dropped dramatically as did physician interest. By 2002, less than half as many ablative resurfacing procedures were performed as were done in 1997.¹⁰

Nonablative Technology

Even though the third-generation Derma-K combination Erbium:YAG/CO₂ laser actually delivered on its promise, few physicians purchased this machine. The rare few who did found out just how good this dual-wavelength technology really is. However, stories of lengthy healing times, redness, scarring and skin-whitening problems associated with fully ablative laser resurfacing fueled interest in wrinkle-reduction without the need for surface skin healing: so-called “subsurface collagen remodeling” or “nonablative wrinkle reduction.”¹¹

These “new and safer” techniques for wrinkle reduction were talked about in fashion, style and self-improvement magazines. They involve use of low-energy infrared lasers (Cooltouch, Titan, Aluma, ReFirme, LuxIR), intensified pulsed light (Photoderm, Fotofacial) or radiofrequency energy (Thermage, TheraCool, Polaris) to stimulate collagen and elastic fiber production below the skin surface (reducing wrinkles) with little or no damage to the surface of the skin, which means little or no healing is required. Plasma treatment (Rhytec-Portrait), another technique, uses a plasma-generating technology to thermally heat skin and thereby stimulate collagen formation. Another form of

Effects of CO₂/Erbium: Yag Laser Resurfacing



ABOVE: A 48-year-old woman before and after (four weeks post-op) CO₂/Erbium:YAG laser resurfacing and dermal graft lip enlargement.

RIGHT: A 65-year-old woman before and after CO₂/Erbium:YAG laser resurfacing.



All photos courtesy of Richard Tholen

nonsurgical wrinkle reduction involved the use of a pulsed dye laser (this laser has been in clinical use since 1988 for the treatment of port wine stain birthmarks) re-engineered to stimulate the tiny capillaries just below the skin's surface to release factors that cause collagen to form, improving the tone and texture of the skin. Treatment with this laser, called N-Lite, was shown to reverse a portion of the inevitable loss of collagen in the upper layers of the skin that occurs as we age (we lose about 1% per year after age 40).

These subsurface wrinkle treatments deliver pulsed light or other stimulating energy to the deeper skin layers in an effort to reduce the visibility of sun damage or wrinkles. They are mild and nonspecific, and multiple treatments are required to provide minimal incremental improvement.¹² In our experience, only one-third of patients treated with the N-Lite laser experienced some visible degree of improvement, and it was usually subtle. The remaining two-thirds of patients treated with this device showed essentially no improvement.

Although the manufacturers of these technologies promise less downtime for healing, the reality is that some patients may have redness or blistering of treated areas. Some of these treatments are actually quite uncomfortable, and multiple treatments are almost always required. In addition, final results cannot be seen until months after treatment. Results are often described as “modest”¹³ or “less than with traditional CO₂ or Er:YAG resurfacing techniques.”¹⁴

In contrast, a carefully performed TCA facial peel will often yield similar results and require only a few days of downtime for recovery.

.....
Fractional Laser Treatment

In the past several years, both Erbium:YAG and CO₂ lasers have been re-engineered into fractional laser resurfacing machines, which are promoted as offering “results as good as ablative resurfacing without the healing downtime or redness.” Fraxel, made by Solta Medical, was the first and is one of the most publicized fractional laser systems in use today. Other fractional lasers include Pixel (Alma Lasers), activeFX (Lumenis Laser) and StarLux (Palomar). They basically use either Erbium:YAG or CO₂ wavelength lasers focused into extremely tiny beams that vaporize tiny holes in the skin. Separated by undamaged skin, they make a “polka-dot” pattern. The type (wavelength) of laser and the intensity of the laser beam, which determines the size and depth of the tiny holes in the skin, and the density (spacing) of the holes, determine the amount of injury, healing time and improvement.

Although some doctors and websites claim “no healing” or “minimal downtime,” each patient still has to go through the discomfort associated with healing of the vaporized laser holes, which can take a week or longer. The real benefit of fractional laser is the lack of significant thermal damage, which pre-

How the Procedures Are Performed

Laser resurfacing procedures require at least a clean procedure room with aseptic technique or an outpatient operating room and some form of pain control.

Minor procedures for small areas such as the crow's foot region, the area around the mouth, or patches of acne or other scarring can take 15 to 30 minutes. Local anesthesia is usually sufficient to control pain.

Larger areas, or an entire face, can take one to two hours or so (depending on type of laser, severity of wrinkles or scarring, and skill and experience of the surgeon) and will require at least local anesthesia plus IV sedation or a mild general anesthetic. Accuracy of the procedure (especially around the eyelids, nostrils, lips, brows and scalp) and patient comfort are often enhanced by using general anesthesia.

After a short time in the recovery area, the patient is discharged home. Postoperative care involves use of antibiotics to reduce the risk of infection, an antiviral medication to reduce the chance of a herpes outbreak, and Tylenol or mild prescription pain medication. The pain after laser resurfacing is somewhat less than that associated with dermabrasion or chemical peels, as nerve endings and blood vessels are sealed by the laser. Still, the operation is not painless.

Some manufacturers or providers claim fast recovery from laser resurfacing, but skin injury by any technique still requires about a week of healing. One pass with an Ultra-pulse laser may heal in just short of a week, but will have removed only the tiniest lines or wrinkles. More rapid healing can be seen with one pass of an Erbium:YAG laser, as only the epidermis is removed; however, the degree of improvement is small.

Proper education and experience are required to ensure surgeons to know the number of passes and the proper amount of energy per pass to use, as well as how to feather the edges. Claims of rapid healing by some laser manufacturers and physicians usually reflect the fact that less tissue is removed. These patient may heal faster and have less redness, but they also have less dramatic results.

vents the hypopigmentation problems caused by the older CO₂ lasers.

Fractional laser practitioners usually recommend that patients undergo several treatments to achieve the desired results because each fractional procedure vaporizes between 15% and 25% of

the skin. Three to six sessions, each one requiring the laser operation and a week or so of healing are “recommended” for optimum results. Many fractional laser surgeons overstate the final result, calling it equal or superior to that of fully ablative procedures while costing less and requiring less downtime. However, add up the time required for each session, the cumulative time spent healing and making doctor’s office visits, and the cost of each treatment, and it’s questionable whether they do indeed cost less. Many patients have been disappointed with the results of fractional laser treatment despite multiple sessions, especially when they realize they spent more time and money than they would have for a single full-face ablative procedure.¹⁵

Fractional laser treatments do indeed work, but the results are only a “fraction” of what is achieved with fully ablative laser resurfacing where the entire skin surface is lasered, rather than just a “fraction” of the skin surface. And healing still takes five to seven days or more with more aggressive treatment.¹⁶ In comparison, full-face ablative laser resurfacing is uncomfortable for a day or two and requires messy skin care for about a week. Only half of patients receiving fractional laser treatments believe them to be worthwhile. This may be more an indictment of some physicians’ inflation of patient expectations than of the technology itself.

Summary

Unfortunately, a jump-on-the-bandwagon mentality caused many physicians to buy expensive first- or second-generation lasers. What followed were cases of patients who had long healing times, excessive redness, or who ultimately developed hypopigmentation or lines of demarcation. Other patients had great expectations, but after healing experienced very little improvement. Cases of patients with burns and scars generated bad press and lawsuits, and the pendulum of public opinion began to swing toward condemnation of so-called ablative skin resurfacing. Physicians who were careful used their lasers less frequently and with less energy to avoid problems; but their patients had less-dramatic results. Some physicians just gave up and put their lasers into storage or sold them. Others turned to nonablative and fractional laser technologies.

All of these technologies are still in use, although the company names, the laser “boxes” (not the fundamental wavelength spot sizes or energies), and the marketing and advertising have continued to change to try to attract both physicians and patients.

Irrespective of the laser technology *du jour*, one thing has remained constant: Physicians with little or no prior cosmetic surgery experience, laser training or wound care expertise have sought to capitalize on the public’s fascination with surgical lasers and have been doing procedures on every patient they can aim their laser at—often for \$5,000 to \$8,000 or more per pro-

cedure or series of treatments.

Operator experience and skill are much more critical than the technology used for facial resurfacing. Patients should seek physicians who are proficient in numerous laser and nonlaser technologies in order to receive the best advice regarding their care. **MM**

Richard Tholen is president of Minneapolis Plastic Surgery.

REFERENCES

1. Riggs K, Keller M, Humphreys TR. Ablative laser resurfacing: high-energy pulsed carbon dioxide and erbium:yttrium-aluminum-garnet. *Clin Dermatol*. 2007 Sep-Oct;25(5):462-73.
2. Fitzpatrick RE. Maximizing benefits and minimizing risk with CO2 laser resurfacing. *Dermatol Clin*. 2002 Jan;20(1):77-86.
3. Chwalek J, Goldberg DJ. Ablative skin resurfacing. *Curr Prob Dermatol*. 2011;42:40-7.
4. Alster T, Hirsch R. Single-pass CO2 laser skin resurfacing of light and dark skin: extended experience with 52 patients.
5. Alster t, Lupton JR. Erbium:YAG cutaneous laser resurfacing. *Dermatol Clin*. 2001 Jul;19(3):453-66.
6. Tanzi EL, Alster TS. Single-pass carbon dioxide versus multiple-pass Er:YAG laser skin resurfacing: a comparison of postoperative wound healing and side-effect rates. *Dermatol Surg*. 2003 Jan;29(1):80-4.
7. Goldman MP, Marchell N, Fitzpatrick RE. Laser skin resurfacing of the face with a combined CO2/Er:YAG laser. *Dermatol Surg*. 2000 Feb;26(2):102-4.
8. Zachary CB. Modulating the Er:YAG laser. *Lasers Surg Med*. 2000;26(2):223-6.
9. Trelles MA, Garcia-Solana L, Calderhead RG. Skin resurfacing improved with a new dual-wavelength Er:YAG/CO2 laser system: a comparative study. *J Clin Laser Med Surg*. 1999 Jun;17(3):99-104.
10. ASAPS, American Society for Aesthetic Plastic Surgery. Available at: www.surgery.org/media/statistics ASAPS Statistics: Complete charts (pdf) 1997 – present.
11. Goldberg DJ. Lasers for facial rejuvenation. *Am J Clin Dermatol*. 2003;4(4):225-34.
12. Menaker GM, Wrone DA, Williams RM, Moy RL. Treatment of facial rhytids with a nonablative laser: a clinical and histologic study. *Dermatol Surg*. 1999 Jun;25(6):440-4.
13. Fritz M, Counters JT, Zelickson BD. Radiofrequency treatment for middle and lower face laxity. *Arch Facial Plast Surg*. 2004 Nov-Dec;6(6):370-3.
14. Ciocon DH, Doshi D, Goldberg DJ. Non-ablative lasers. *Curr Probl Dermatol*. 2011;42:48-55.
15. Karsai S, Czarnecka A, Junger M, Raulin C. Ablative fractional lasers (CO2 and Er:YAG): a randomized controlled double-blind split-face trial of the treatment of peri-orbital rhytides. *Lasers Surg Med*. 2010 Feb;42(2):160-7.
16. Alexiades-Armenakas MR, Dover JS, Arndt KA. The spectrum of laser skin resurfacing: nonablative, fractional, and ablative laser resurfacing. *J Am Acad Dermatol*. 2008 May;58(5):719-37.

Craniosynostosis and Deformational Plagiocephaly

When and How to Intervene

By Robert J. Wood, M.D., FACS, FAAP

■ Craniosynostosis, a congenital deformity in which one or more of the sutures between the bones of the cranial vault fuse prematurely, is a relatively rare condition that is usually obvious just after birth. Deformational plagiocephaly is much more common and usually becomes apparent by 2 months of age. Although the head of a baby with deformational plagiocephaly may appear flat on one side, deformational plagiocephaly does not affect brain function. Craniosynostosis, however, may impair brain growth and development and, thus, is far more serious. Babies with irregularly shaped heads that are concerning should be evaluated by a craniofacial surgeon. This article provides an overview of the physical signs of craniosynostosis and deformational plagiocephaly as well as an update on treatment.

.....

Most newborns have head shapes that are within normal limits. If a baby's skull shape is noticeably irregular, craniosynostosis or deformational plagiocephaly are the mostly likely causes. Craniosynostosis is relatively rare. It occurs in only one of every 2,000 births and is usually obvious immediately after birth.¹ Deformational plagiocephaly is much more common, and it usually becomes apparent by the time a baby is 2 months old. Babies who have irregularly shaped heads that are concerning should be evaluated by a craniofacial surgeon and treated within the first four to six months of life. Because the treatments for craniosynostosis and deformational plagiocephaly differ, it is important that the child's condition is correctly identified. What follows is an overview of the classic physical signs of these conditions and an update on treatment.

.....

Distinguishing Between Conditions

Craniosynostosis is a congenital deformity in which one or more of the sutures between the bones of the cranial vault fuse prematurely. With craniosynostosis, the skull becomes deformed, and brain growth and development may be impaired. Increased intracranial pressure, seizures and developmental delays can occur if craniosynostosis is not corrected. A physical exam is often sufficient to make a preliminary diagnosis. A CT scan may be used to confirm craniosynostosis.

Patients with single-suture craniosynostosis have distinct head shapes that correlate with the specific suture that has closed. A palpable ridge along the suture is typically present and can be felt upon physical examination. Growth occurs perpendicular to the closed suture, yielding the associated head shape. The condition can manifest in a number of ways:

- Scaphocephaly (sagittal synostosis) results when the bony plates along the midline cranial suture close prematurely. Typically, children with this condition have a long, narrow head. The forehead protrudes, the back of the head is prominent and the top of the head may be arched (Figure 1A).
- Trigenocephaly (metopic synostosis) is caused when the midline suture fuses the two bones of the forehead. Children with this condition tend to have a triangular or keel-shaped forehead. The distance between the eyes might be narrower than usual, a condition known as hypotelorism (Figure 1B).
- With synostotic anterior plagiocephaly (unilateral coronal synostosis), the suture on one side of the front of the head is affected. This causes a recessed and flattened forehead, an elevated and widened palpebral aperture on the affected side, a tilted nose and a cheek swept back posteriorly on the affected side (Figure 1C).

- Synostotic posterior plagiocephaly (lambdoid synostosis) is caused when the bones on the side and back of the head fuse prematurely. It results in a flattened area on the side of the synostosis. The back of the head shifts to the unaffected side, and the mastoid process may bulge. The condition is rare and can be confused with deformational posterior plagiocephaly (Figure 1D).

Craniosynostosis is more severe when more than one suture is involved. Multiple-suture craniosynostosis is associated with as many as 70 syndromes. Apert, Crouzon, Pfeiffer, Saethre-Chotzen and Muenke are the most common.

Multiple-suture craniosynostosis significantly restricts the skull's ability to expand as the brain grows. As pressure builds on the brain, infants might develop a full or bulging fontanelle, prominent scalp veins, proptosis, increasing head circumference, apnea, seizures and developmental delays. Left untreated, severe increased intracranial pressure may cause blindness and death.

■ Deformational Plagiocephaly

Deformational plagiocephaly, which also refers to a misshapen skull, is both more common and less serious than craniosynostosis. It is frequently accompanied by torticollis, an abnormal neck posture. Although the heads of babies with deformational plagiocephaly may appear flat on one side (eg, the back), the skull's shape does not affect brain function. The incidence of deformational plagiocephaly increased dramatically following the American Academy of Pediatrics' (AAP) recommendation that babies sleep on their backs to reduce the risk of sudden infant death syndrome.

Deformational plagiocephaly (sometimes called positional plagiocephaly) is characterized by a parallelogram-shaped head (Figure 2). In cases of plagiocephaly, the ear on the affected side is sheared forward, and facial features on the same side might be more full. Unlike craniosynostosis, deformational plagiocephaly is caused by pressure outside the skull. Sleeping position and in-utero position may cause this condition. By the mid-1990s, studies linking back-sleeping to plagiocephaly led to new AAP recommendations that parents occasionally turn a sleeping infant's head to avoid deformation.

Up to 85% of babies who have plagiocephaly also have torticollis.² Torticollis is an abnormal neck posture in which the neck is twisted so the head is tipped one way and the chin is rotated another. Consequently, the baby's head may be asymmetrical because the condition causes the child to sleep on one side. Congenital torticollis develops as a result of damage to the neck muscles, nervous system or vascular system, usually from intra-uterine restriction.

..... Treatment

■ Craniosynostosis

Today, treating craniosynostosis involves cranial vault reconstruction by a craniofacial surgeon and a neurosurgeon. A wavy "stealth" incision is made. If the patient has sagittal synostosis,

Figure 1

Single-Suture Craniosynostosis

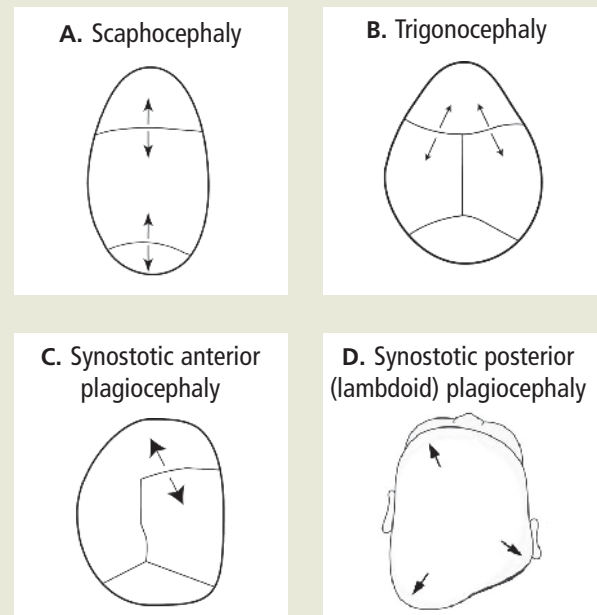
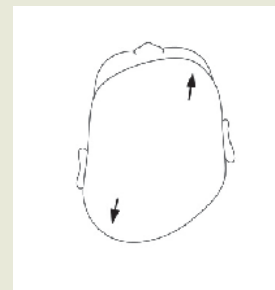


Figure 2

Nonsynostotic Deformational Plagiocephaly



a strip craniectomy will be performed and the bone will be reshaped *in situ*. For patients with other forms of synostosis, a section of bone will be removed, reshaped and fixed into the native skull using resorbable fixation and screws. The procedure can be performed in one to two hours, is safe, and is associated with few complications and greatly improved outcomes. Prior to 1996, steel or titanium plates were used instead of resorbable material. The procedure required much longer operative times and resulted in considerably more blood loss. Older fixation techniques also restricted skull growth. A study published in *Plastic and Reconstructive Surgery* in 2004 describes a combined prospective and retrospective analysis done on 1,883 patients younger than 2 years of age with craniosynostosis who

CASE STUDY

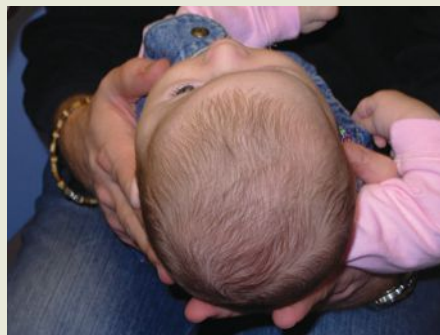Child with Left Coronal Craniosynostosis

A 2-month-old girl came to our clinic with a left brow retraction that had been noted shortly after birth and had remained unchanged. The baby was on track developmentally, and her health history was otherwise unremarkable.

During the physical exam, left frontal plagiocephaly was noted. The supraorbital rim was seen to be behind the level of the cornea. Slight ridging was observed along the coronal suture, but there was no other sutural ridging. The anterior fontanelle was patent and soft. The patient's occipital frontal circumference was 37.5 cm. A CT scan showed bony fusion of the left coronal cranial suture consistent with craniosynostosis.

When the patient was 6 months old, a cranial vault remodeling procedure was performed to advance the frontal bone. A bicoronal "stealth" incision was made. Craniotomy was performed, along with osteotomies to free the frontal bone bilaterally, including the superior orbits. Using resorbable plates and screws, the bones were remodeled and fixed with the brow advanced forward. The scalp was closed with resorbable sutures. Jackson Pratt drains were placed. The patient was extubated in the OR, monitored overnight in the PICU and discharged four days later.

The patient was seen three weeks postoperatively and at six months postoperatively. She has since been evaluated annually. She experienced no complications, her cranial contour remained within the normal range and there were no residual cranial defects.



Photos: Gillette Children's Specialty Healthcare

When seen from this angle, the left brow retraction is obvious and the supraorbital rim is noticeably offset compared with the right rim.



At several years postcraniotomy, the left coronal craniosynostosis is virtually undetectable.

were treated by 12 surgeons from seven geographic areas over a five-year period. In all cases, the same type of resorbable bone-fixation devices (poly-L-lactidpolyglycolic copolymer) was used. The analysis found only 0.2% of patients experienced significant infectious complications, 0.3% experienced device instability (primarily resulting from postoperative trauma), and 0.7% had self-limiting local foreign-body reactions.³ In our practice, we have had no incidents of brain injury or mortality in craniosynostosis repair.

Typically, patients can be released from the hospital within three to four days following surgery. Postoperatively, babies can be fed, bathed and held normally. They do not need to wear helmets. Within nine to 15 months after surgery, the polymer fixation will be completely absorbed and replaced by the child's own cranial bone.

■ Deformational Plagiocephaly

For mild cases of deformational plagiocephaly, treatment generally includes positioning and/or orthosis therapy. During the first three to four months after birth, consistent repositioning of a sleeping infant's head often leads to spontaneous rounding of a skull with mild flattening. Increasing the time infants spend lying on their stomachs or sides—while supervised—is helpful as well.

In moderate to severe cases of deformational plagiocephaly, or when a trial of counter-positioning has failed, physicians might recommend a cranial remodeling orthosis. Orthoses are most effective for children 4 to 8 months of age; the usual length of treatment is two to three months.

Physical therapy is successful in treating torticollis 95% of the time. Therapy usually lasts two to three months. After develop-



Preoperatively, this infant boy had the classic long, narrow head shape associated with scaphocephaly.



Postoperative result with normal head shape.

Photos: Gillette Children's Specialty Healthcare

CASE STUDY

Child with Scaphocephaly

A boy was referred to Gillette Children's Specialty Healthcare at 7½ weeks of age for evaluation of an abnormal head shape. The patient was delivered vaginally, full-term, after an uncomplicated pregnancy. Family history was negative for syndromal diagnoses or other neurologic disorders. Prominent frontal bossing was also noted at birth. The boy's family described him as having a large head, although they felt it had decreased in size somewhat since birth.

Upon examination, a long, narrow head shape (scaphocephaly) was evident. Ridging coursed along the anterior two-thirds of the sagittal suture. The anterior fontanelle was patent and approximately the size of a fingertip. Frontal and occipital bossing were noted. The patient's occipital frontal circumference at 7½ weeks was 44 cm, which placed him in the 98th percentile for his age. His neurological exam was normal, and he was developmentally on track for his age.

Radiographs and 3-D reconstructions revealed closure of the anterior two-thirds of the sagittal suture. An axial CT scan showed some intracranial blood, consistent with a small subdural hematoma associated with birth. There were no mass effect, ventricular enlargement or brain malformations.

The patient underwent a near total calvarial remodeling surgery. A bicoronal, wavy "stealth" incision was made in the scalp, and a strip craniectomy was performed. Approximately 4 cm of bone was removed along the sagittal suture, starting at the coronal sutures and coursing posteriorly to the lambdoid sagittal sutural junction. Triangular-shaped pieces of bone were removed at the lambdoid sagittal junctions. Barrel stave osteotomies were performed at the cranial base, widening the cranium. Vascularized parietal bone flaps were fashioned. The scalp was closed with resorbable sutures. The patient was extubated in the OR, monitored overnight in the PICU and discharged after four days.

The child was seen in clinic at three weeks and six months postoperatively. Subsequently, he was evaluated annually until he was 4 years old. He has experienced no complications, his cranial contour has remained within the normal range, and he has no residual cranial defects.

ing a care plan, therapists teach parents exercises they can do at home to help infants gain mobility. When needed, a simple muscle-release procedure is performed. However, surgery is necessary in less than 5% of cases.

Conclusion

Early diagnosis is important for children who have craniosynostosis. When physicians suspect that a child may have the condition, they should immediately refer the patient to a craniofacial surgeon for evaluation. The goals of surgery are to prevent brain damage and to reduce deformity. Deformational plagiocephaly should also be treated during the first six months of a child's life. Orthotic molding helmets are a useful adjunct. Torticollis, when present, should be treated with physical therapy, and with surgery only when refractory. **MM**

Robert J. Wood is a craniofacial surgeon and medical program director for the Center for Craniofacial Services at Gillette Children's Specialty Healthcare. He also is a clinical associate professor at the University of Minnesota.

REFERENCES

1. Jane JA Jr, Wyler AR. Surgery for craniosynostosis. Medscape Reference. Available at: <http://emedicine.medscape.com/article/248568-overview#a0199>. Accessed May 3, 2012.
2. Fish D, Lima D. An overview of positional plagiocephaly and cranial remodeling orthoses. JPO: J Orthotics Prosthetics. 2003;15(2):37-47.
3. Eppley B, Morales L, Wood R, et al. Resorbable PLLA-PGA plate and screw fixation in pediatric craniofacial surgery: clinical experience in 1883 patients. Plast Reconstr Surg. 2004;114(4):850-6.

Be careful what you fish for

Encourage safe consumption of finny fare.

By Craig Bowron, M.D.

Although fish are an excellent source of protein, a couple of things should be considered when adding them to your diet. Sometimes they don't want to be caught, and sometimes even a filleted fish can fight back: A walleye bone once harpooned itself so deeply into one of my tonsils that it took an ENT colleague to remove the nubbin that was giving me a "hooked" sensation. And then there's the element mercury (Hg) to consider, hanging out right where you left it back in college chemistry between gold (Au) and thallium (Tl) on the sixth row of the Periodic Table. Whether college was 10 years ago or 30, mercury exposure through fish consumption remains an important issue, and a new study by the Minnesota Department of Health shows that we can't let our guard down (www.health.state.mn.us/divs/eh/hazardous/topics/studies/newbornhg1sp.html).

Researchers tested mercury levels in blood from routine newborn screening for congenital conditions. They looked at samples taken between 2008 and 2010 from 1,465 babies whose mothers resided near Lake Superior in Minnesota, Wisconsin or Michigan. Eight percent of the newborns had mercury levels above the EPA's safe-dose limit for methyl mercury (the primary form of found in fish). The highest concentrations were measured in those born during the summer, which supports exposure through local fish consumption and is consistent with fish consumption—not thermometers or dental fillings—being the largest source of human mercury contamination.

Since there's no scientific evidence that tartar sauce can neutralize mercury, we need to continue to encourage our patients to be more thoughtful about how much and what type of fish they eat. That's particularly true for pregnant women and children under the age of 15 because the developing brain is much more sensitive to methyl mercury's neurotoxic effects.

Here are two simple questions you can ask your patients: Do you eat fish? If so, do you eat fish more than once per week? If that's the case, remind them about the mercury issue and encourage them to eat low-mercury fish. The Department of Health's Safe Eating Guidelines (www.health.state.mn.us/divs/eh/fish/eating/safeeating.html) can help them do just that.

A rule of thumb is the bigger the fish, the more mercury it will have accumulated. Kids under age 15 and women who are pregnant or planning on becoming pregnant can eat pan fish

such as perch, sunfish and crappies once a week. But they should only eat the ones that fit in the pan: no walleyes longer than 20 inches or northern pike longer than 30 inches. For these more mercury-sensitive diners, smaller versions of our state's

most sacred fish—the walleye—can be eaten once a month, as can Minnesota-caught bass and catfish.

For those with culinary wanderlust, the guidelines point out a bevy of low-mercury seafood options and a few high-mercury avoidables such as swordfish and shark.

Although children are more vulnerable to the neurotoxic effects of mercury, adults are by no means immune. Richard Gelfond, CEO of IMAX theaters, funded a research program at Stony Brook University in New York after high mercury levels from his admittedly aggressive "heart-healthy" fish-heavy diet made him severely ataxic. Gelfond's levels were high and his symptoms were obvious; but there's a lot of variation in clinical symptoms because some people seem more sensitive to mercury than others. Until that relationship is better understood, adult diners who are not pregnant can eat low-mercury fish and Minnesota pan fish until they grow gills; but walleyes and northerns should hit the fork just once a week.

But what about "Up North" walleyes pulled from clear, crisp, pristine waters? Aren't they better for us?

Coal-fired power plants are the primary source of inorganic mercury, which travels long distances in the atmosphere before settling. Factors such as water acidity, bacteria found in marshy areas and the presence of sulfur are required to convert it into methyl mercury. This organic form of mercury has a strong affinity for "fishy" proteins so that once

bound, it's almost impossible to clear. The half-life of mercury in humans is 60 to 90 days, but fish keep it for life. Northern Minnesota seems to have most of the conditions required to produce methyl mercury, even though there isn't a smoke stack in sight (see www.seagrant.umn.edu/newsletter/2006/06/readers_want_to_know.html).

Although a week in the northwoods might be the cure for whatever ails you, safe fish consumption guidelines still apply. There are, fortunately, no limits on s'mores. **MM**

Craig Bowron is a hospitalist at Abbott Northwestern Hospital.



**The bigger
the fish, the
more mercury
it will have
accumulated.**